



VITICUSGROUP™
WVC ANNUAL CONFERENCE
MARCH 2 - 5, 2025 | LAS VEGAS, NV

Don't fear the yucky ear! **Paint the cytology instead!**


Christina Gentry DVM DACVD

Assistant Clinical Professor of Veterinary Dermatology

Texas A&M University, College Station, Texas

Agenda 9.30-11.30am

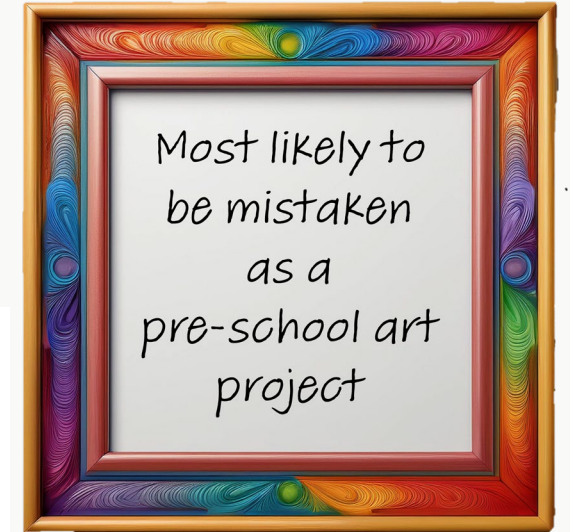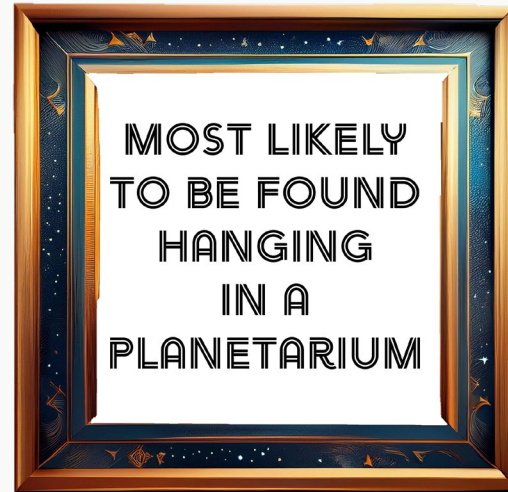
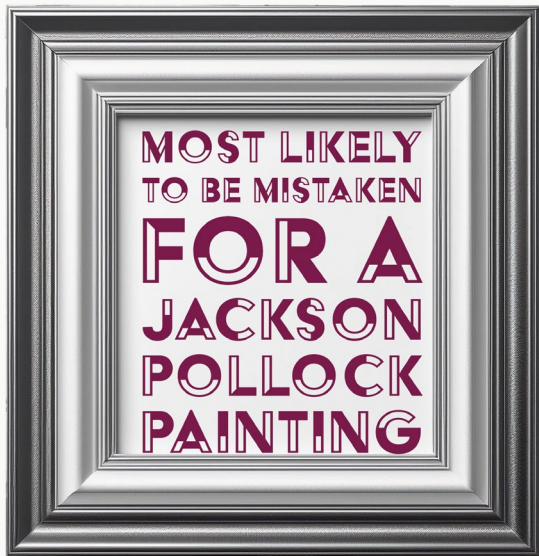- How will the painting work?
- Clinical content: getting started with ear cytology
- PAINT
- Clinical content: the normal ear, the abnormal ear
- PAINT
- Clinical content: Case studies and the complex ear
- PAINT and prizes awarded





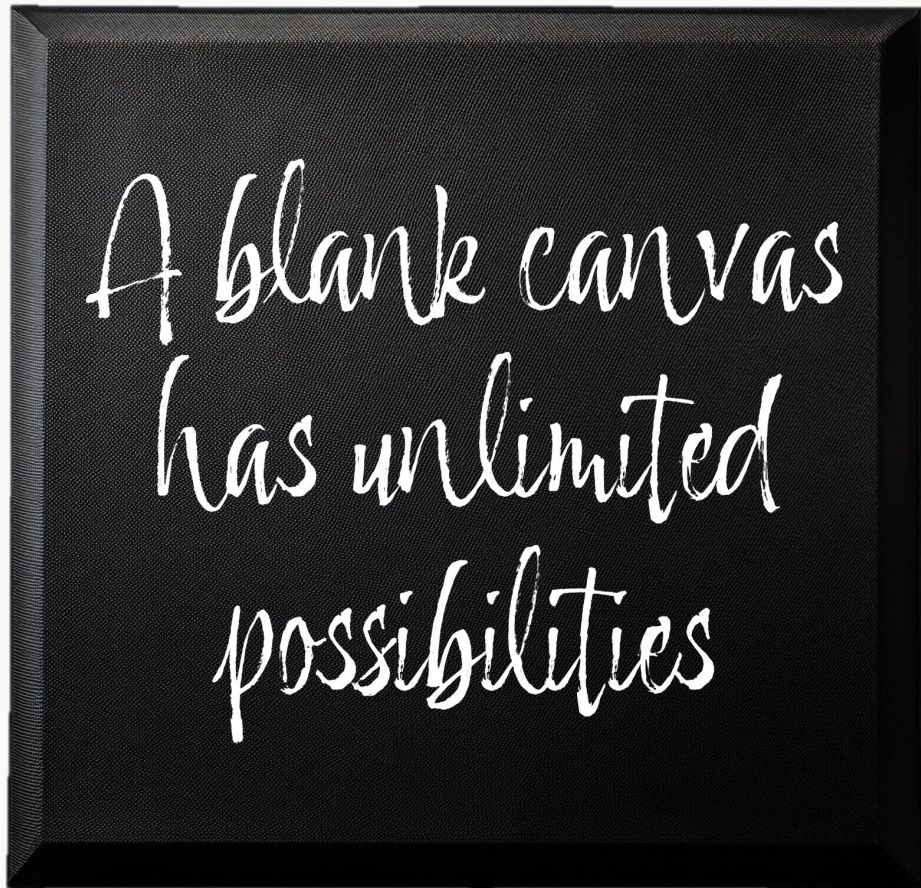
What you will be painting

This is a composite image of a patients' ear cytology from the IDEXX InVue Dx™ Analyzer

Four Premier Awards

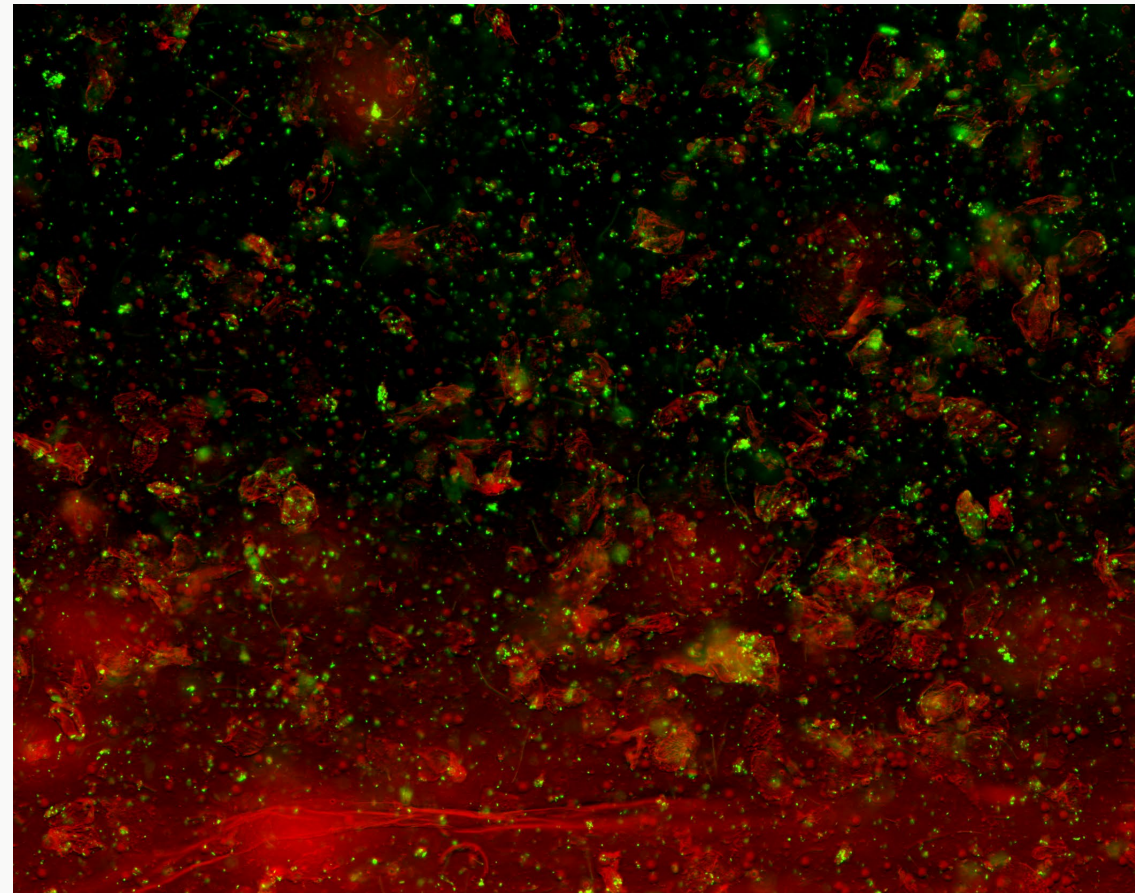


Your Supplies



Tips and Tricks

- ✓ Use water to dilute your paint to create a semi-transparent wash first!
- ✓ Your sponge works well for covering larger areas of the canvas
- ✓ Work on painting your reds and oranges before applying your green paint!
- ✓ You can paint the image in its entirety or only a part of the image – totally up to you!




Financial Disclosure

I have a commercial relationship with Merck Animal Health, but do not believe that it will influence my presentation.

AND


I have a direct relationship with IDEXX. Because of the nature of the relationship, it **will** influence my presentation.





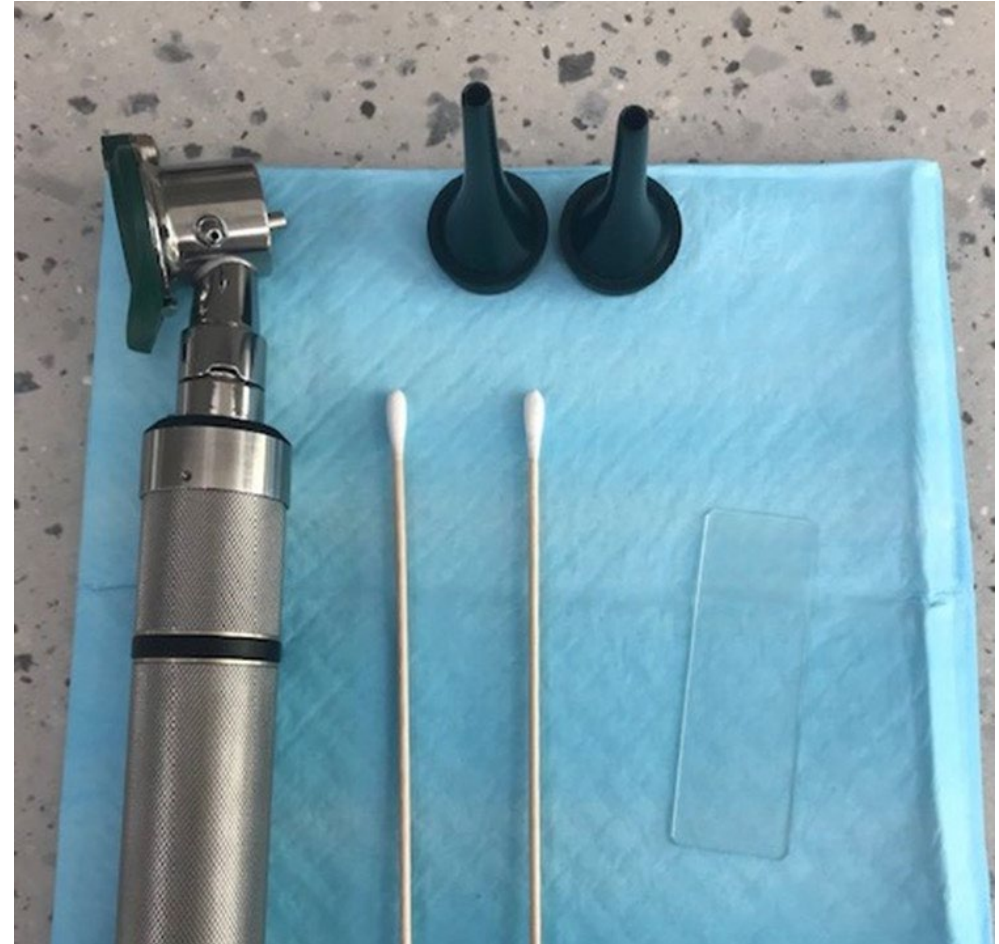Conflict of Interest Disclosure:

The information contained herein is intended to provide general guidance only. As with any diagnosis or treatment you should use clinical discretion with each patient based on a complete evaluation of the patient, including history, physical exam and presentation, and laboratory data. With respect to any drug therapy or monitoring program, you should refer to applicable product insert(s) for complete description of dosage, indications, interactions, and cautions. Diagnosis, treatment, and monitoring should be patient specific and is the responsibility of the veterinarian providing primary care. (2024)



Learning Objectives

- Discuss new technology from IDEXX
- Recognize the significance of common otic pathogens and inflammatory cells.
- Relate cytology results to the otic examination
- Design a treatment plan for otitis externa using cytology and the otic examination
- Consider cases that may benefit from advanced diagnostics and referral



Ear Cytology Collection and Staining

Sample Collection

Cotton tip applicator (CTA) placed into the ear canal until you reach the end of the vertical canal

Spin the CTA along the long axis gently, then remove

****In cases of inflammatory otitis, where otoscopic examination is impossible or impractical, you can still collect an ear cytology**

Traditional Staining

Diff Quick ® modified Romanowsky stain

1. Fixative (light blue)-Methanol (30 sec)
2. Eosinophilic(red)-Xanthene dye (60 sec)
3. Basophilic(dark blue/purple)- Methanol Blue/Azure A (60-90 sec)



Microscope Set up

Ear Cytology Evaluation

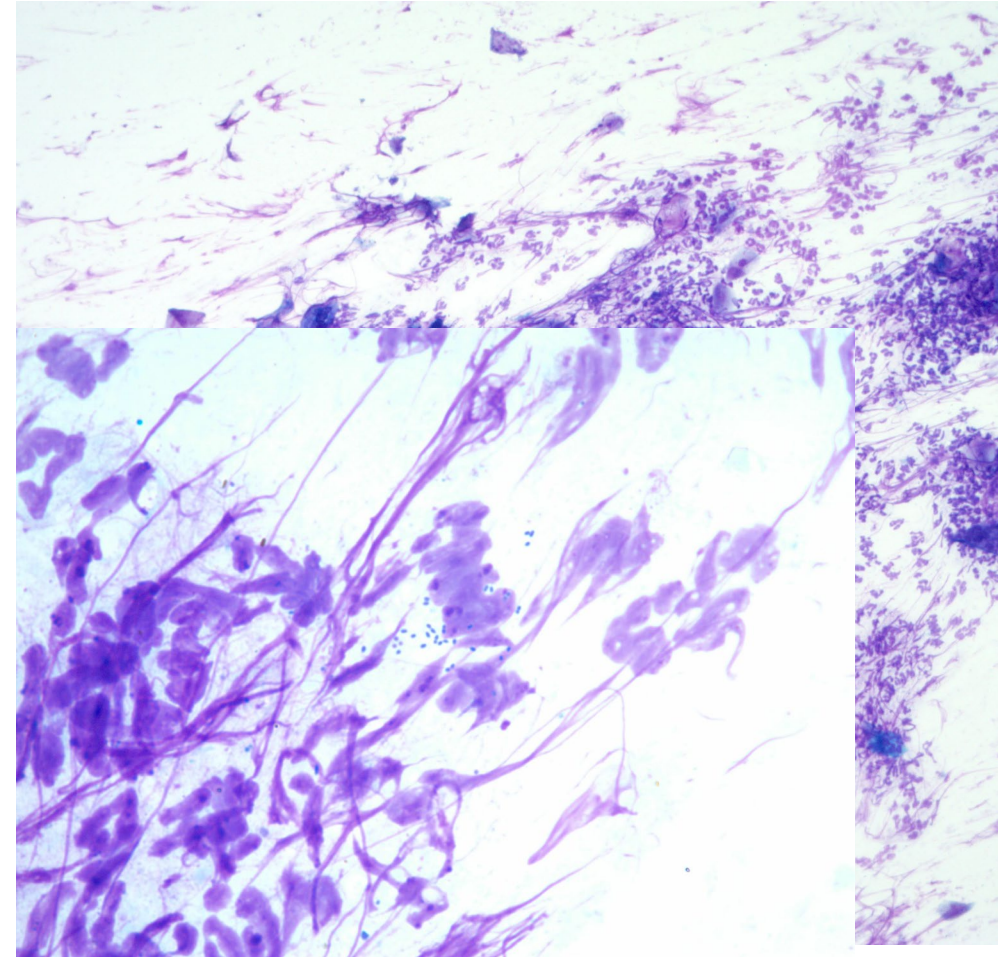
Clean, dedicated microscope used for fine needle aspirates, ear cytology, and skin cytology

Start on 10x objective with the condenser raised and the light at a medium intensity

Locate the area of interest on the slide by scanning for clumps of blue/purplish stain.

Move to 100x objective using immersion oil, keep the condenser raised, and increase light intensity if needed.

Scan through ~10 fields on 100x objective to evaluate for yeast, bacteria, fungal hyphae, and inflammatory cells



10x objective, neutrophils,
keratinocytes

New Technology

IDEXX inVue Dx™ Cellular Analyzer

Sample Collection

Cotton tip applicator (CTA) placed into the ear canal until you reach the end of the vertical canal

Spin the CTA along the long axis gently, then remove

The sample is placed in the reagent and agitated for 10-15 seconds

The reagent mixed with sample are placed onto the cartridge and the cartridge is inserted into the analyzer



1

Put sample in the reagent.



2

Drop sample into cartridge.



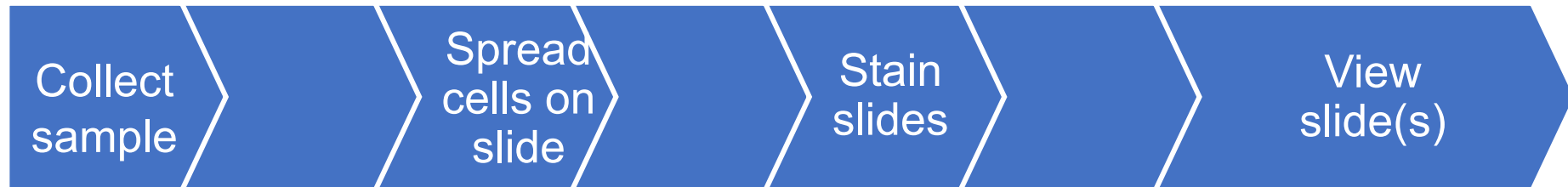3

Insert and press the Start button

IDEXX inVue Dx™ Cellular Analyzer's novel slide-free workflow gives time back to practices

Often interrupted workflow

Microscope



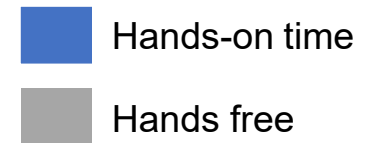
**IDEXX
inVue Dx™**

~1

minute




**10
minutes**




But how does it work???

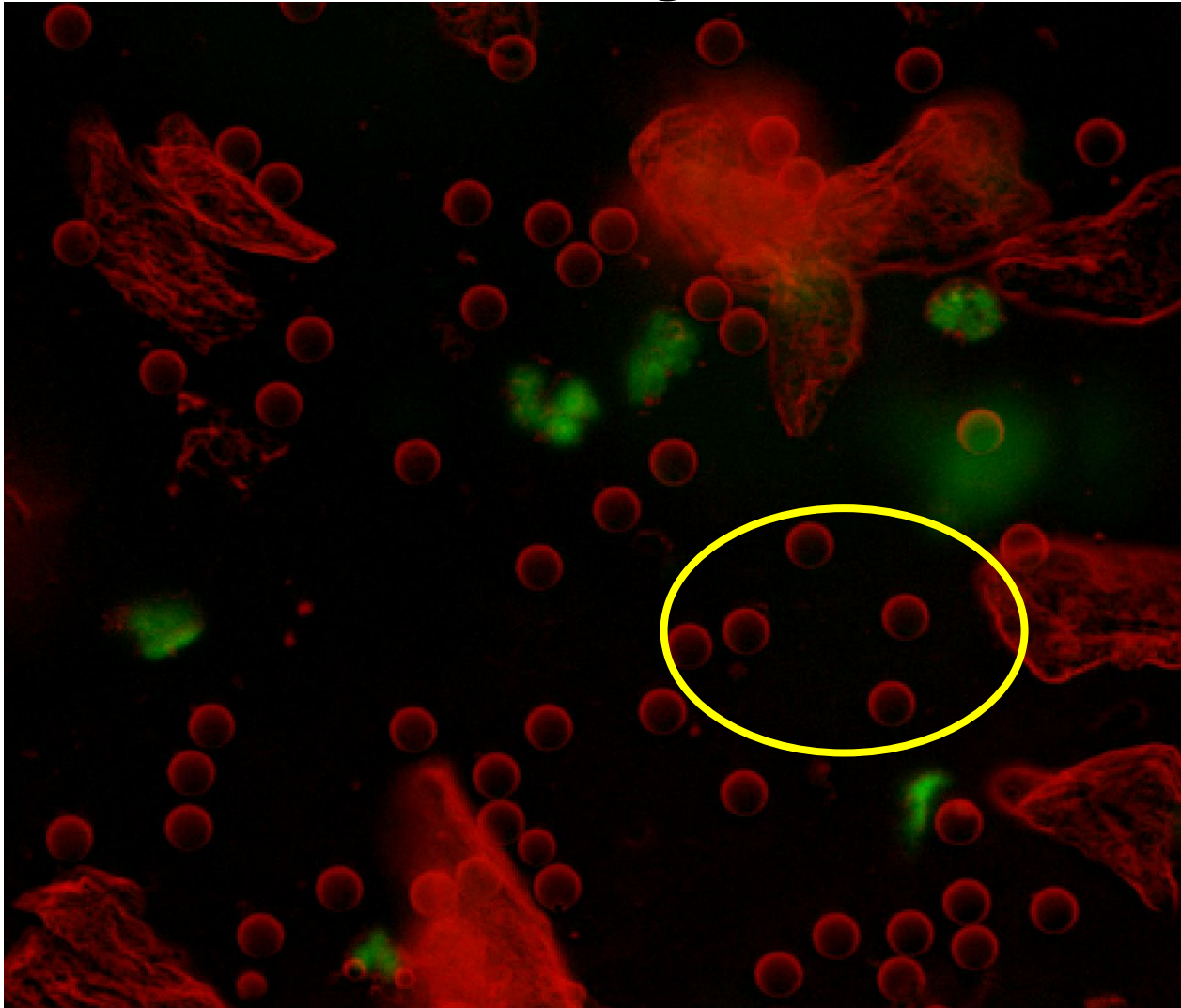
Bright Field Microscopy



Fluorescent Microscopy



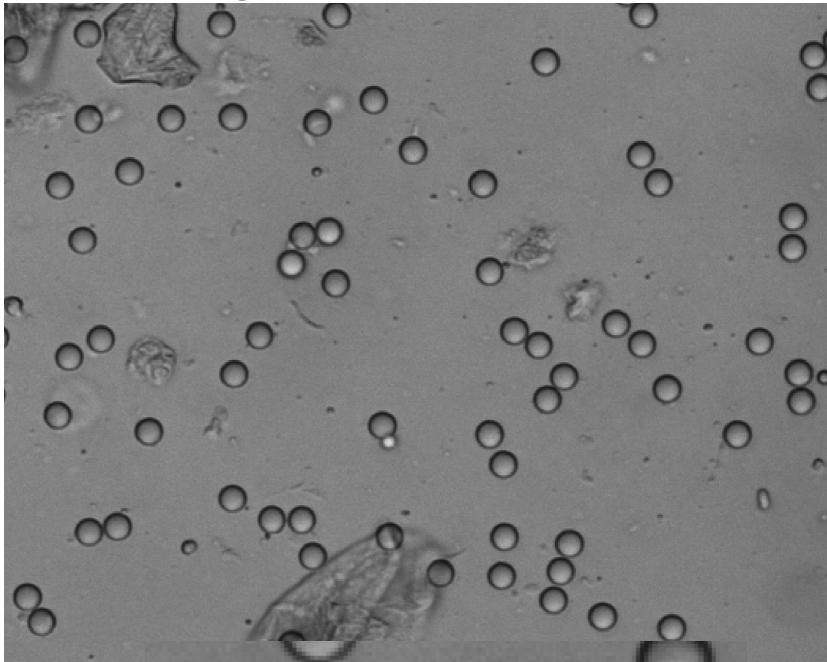
Blending of these images leads to a final image



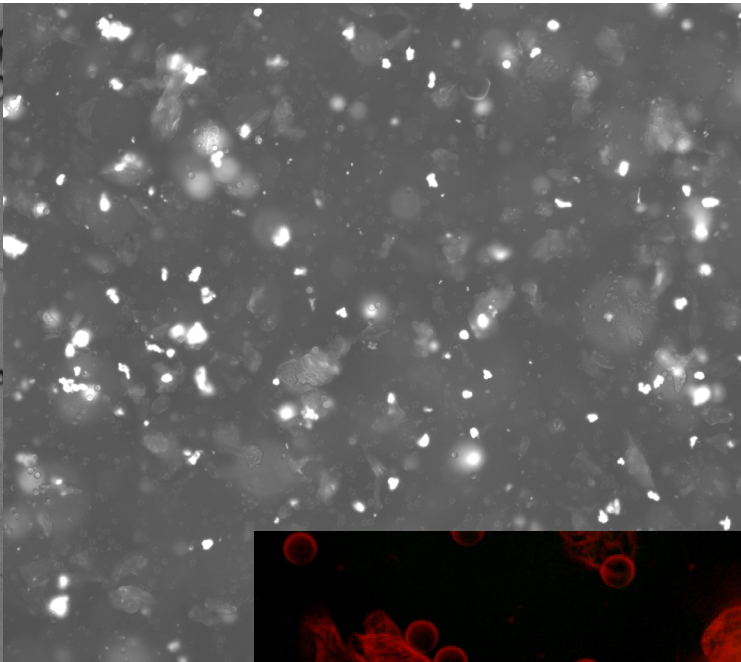
The yellow circle is showing the focus beads

Focus beads tell the analyzer how 'deep' it is looking in the sample and gives the analyzer the ability to look at multiple planes.

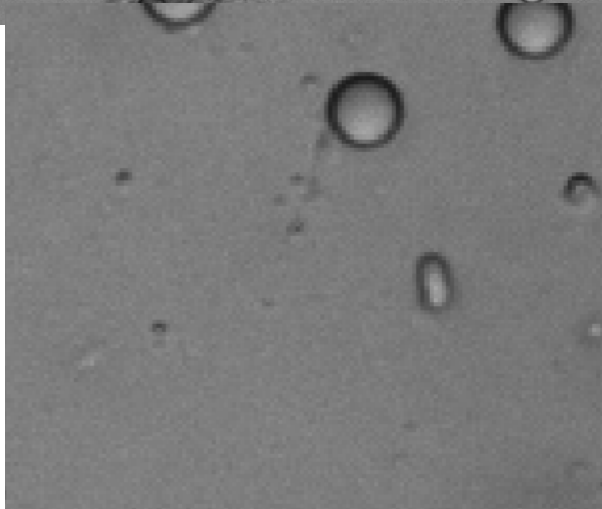
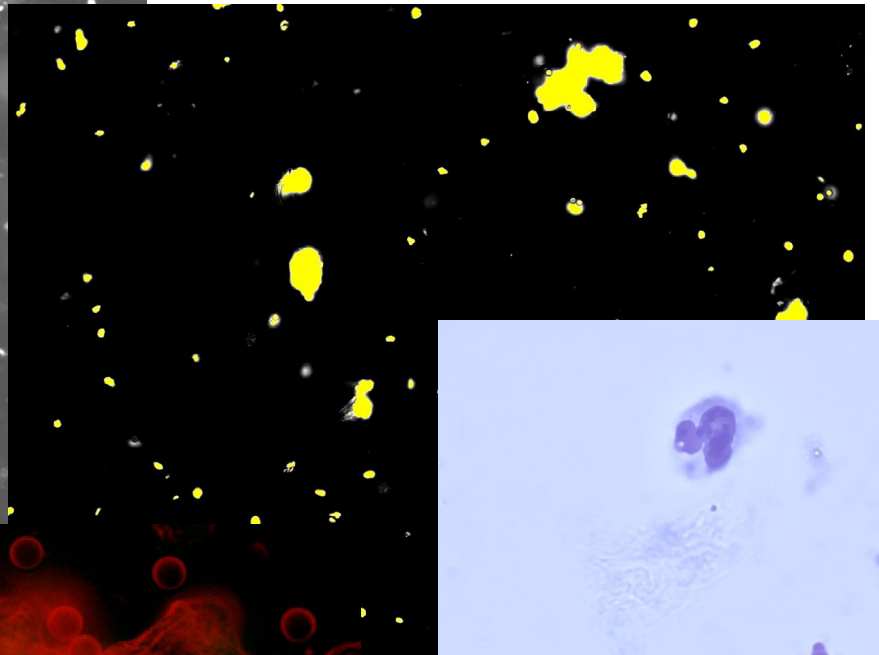
Brightfield 1



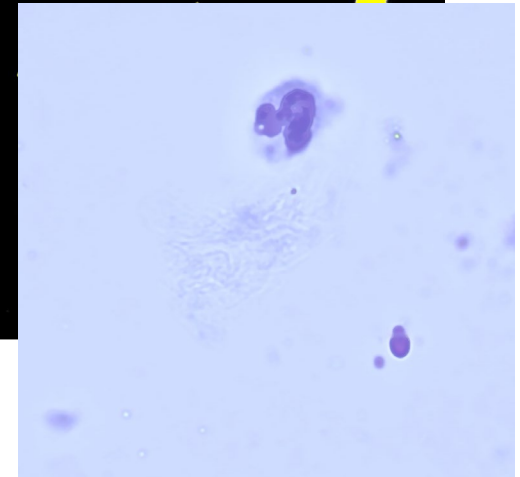
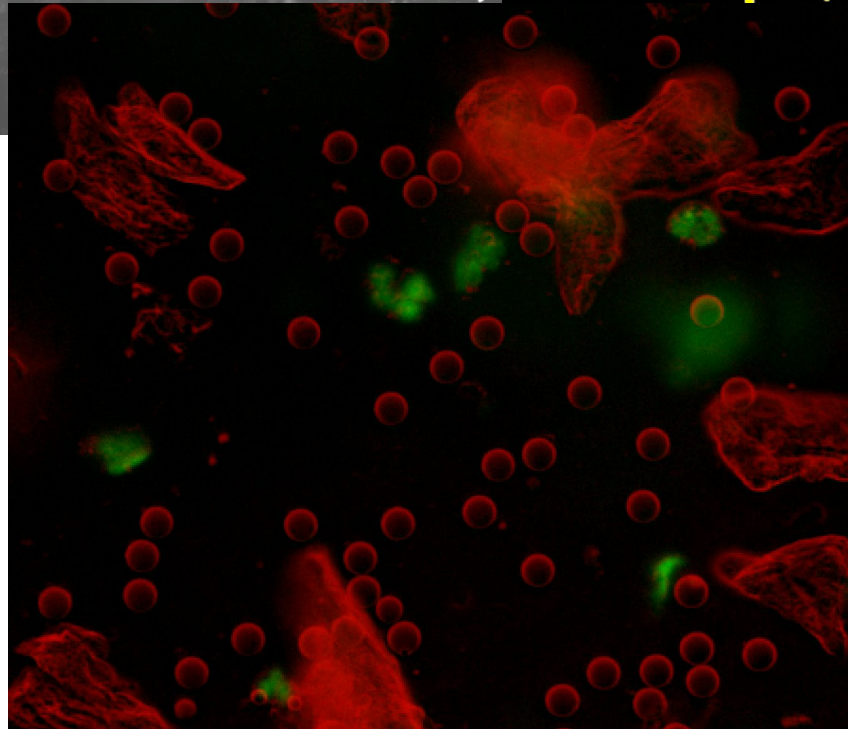
Brightfield 2



Fluorescent




Zoomed in Brightfield 1




Composite
image of WBC
present in ear
sample and
reference glass
image from same
case

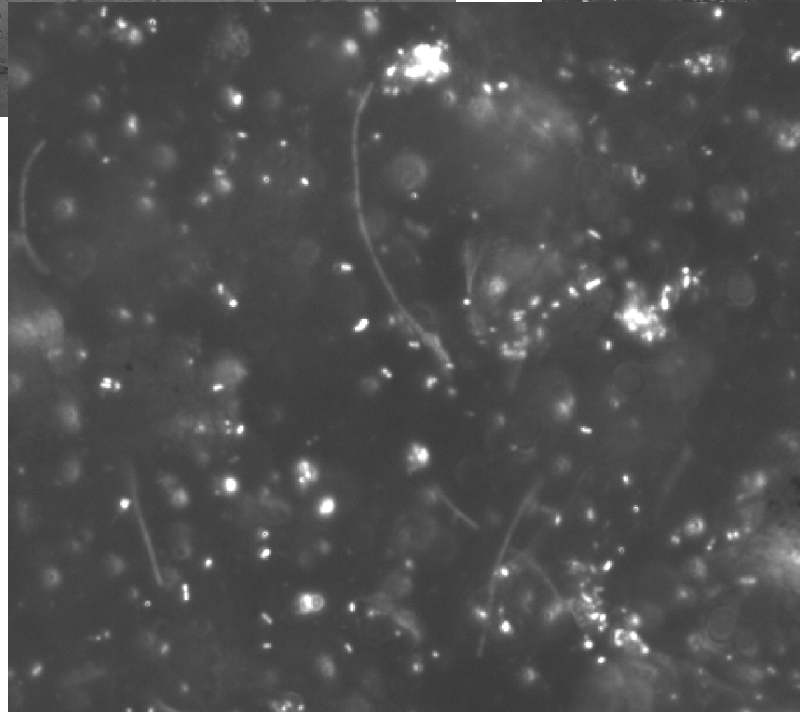
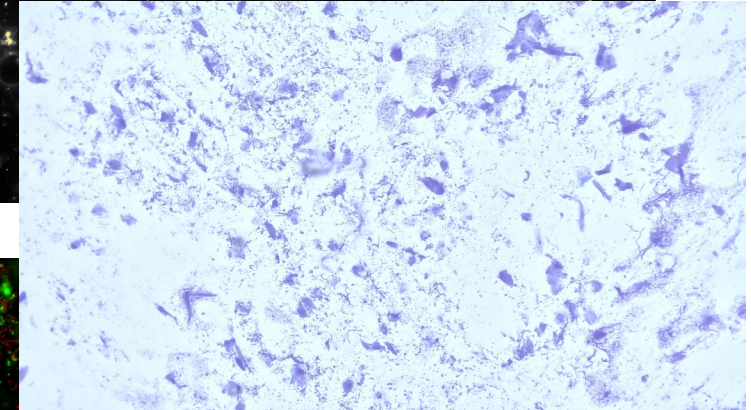

Brightfield 1



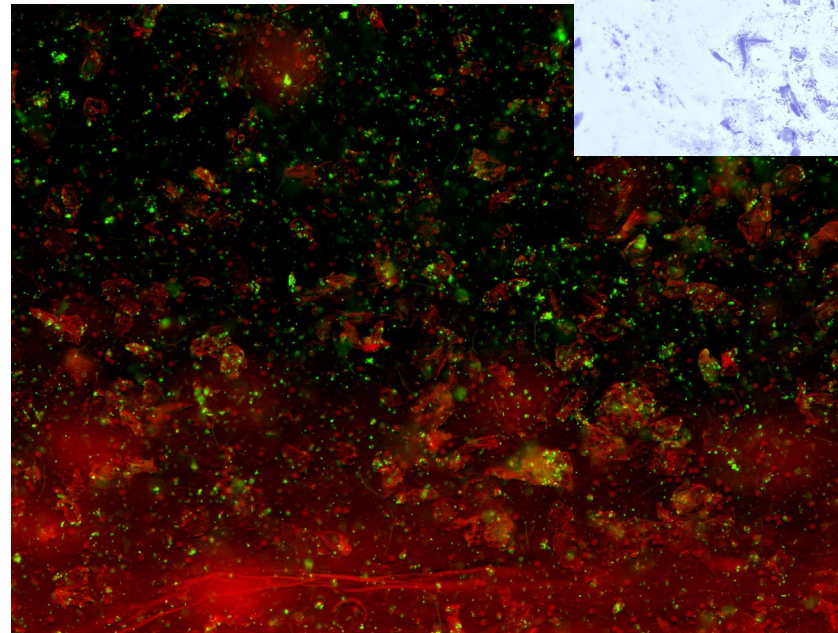
Brightfield 2



Fluorescent

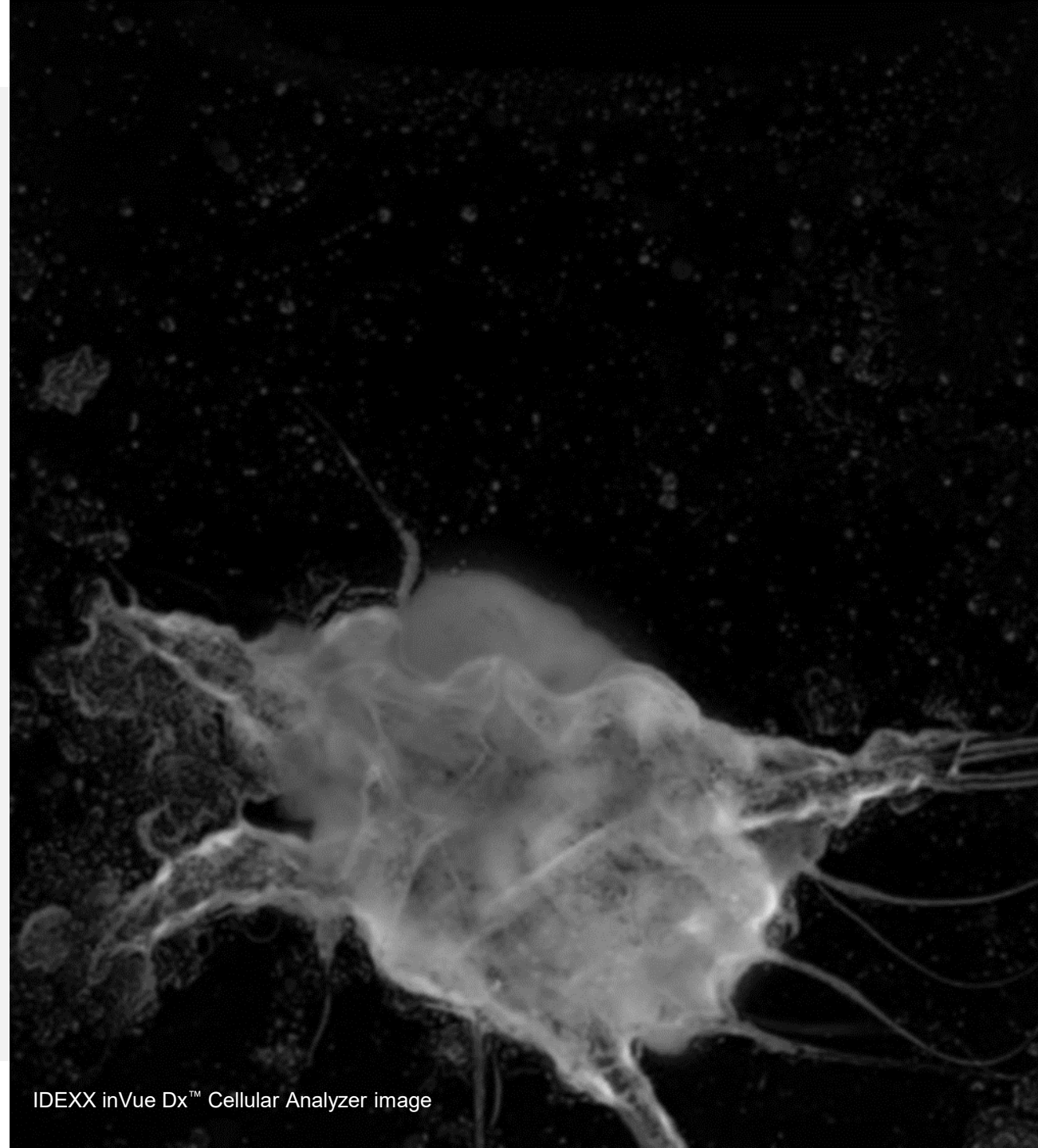


Zoomed in Brightfield 2



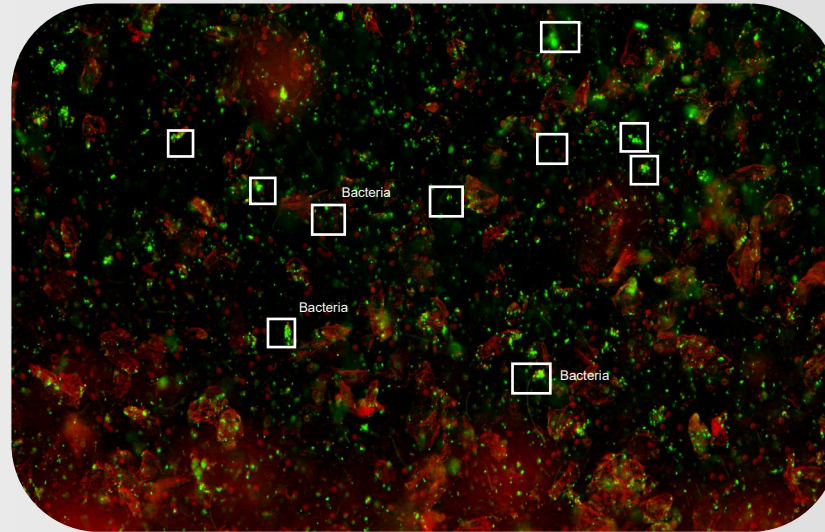
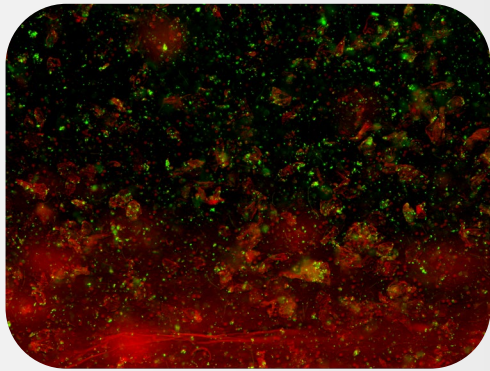
Composite
image of 3-4+
bacteria in ear
sample and
reference glass
image from same
case

IDEXX inVue Dx™
evaluates for mites,
bacteria, yeast, and
white blood cells in a
single run



IDEXX inVue Dx™ Cellular Analyzer image

inVue Dx *automates* processing, classifying, quantifying, and interpreting ear cytology



Deep-learning models trained by IDEXX Reference Lab Pathologists

- Quantification of yeast and bacteria (rods and cocci)
- Assesses for the presence of WBCs
- Assesses for the presence of *Otodectes* mites

IDEXX VetLab Station

SADIE 123456
Canine | Poodle | Female | 4 y | [Profile](#)

2024 Jan 10

[Result Details](#) [Transfer Results](#)

Cytology

1/10/24 8:02 AM

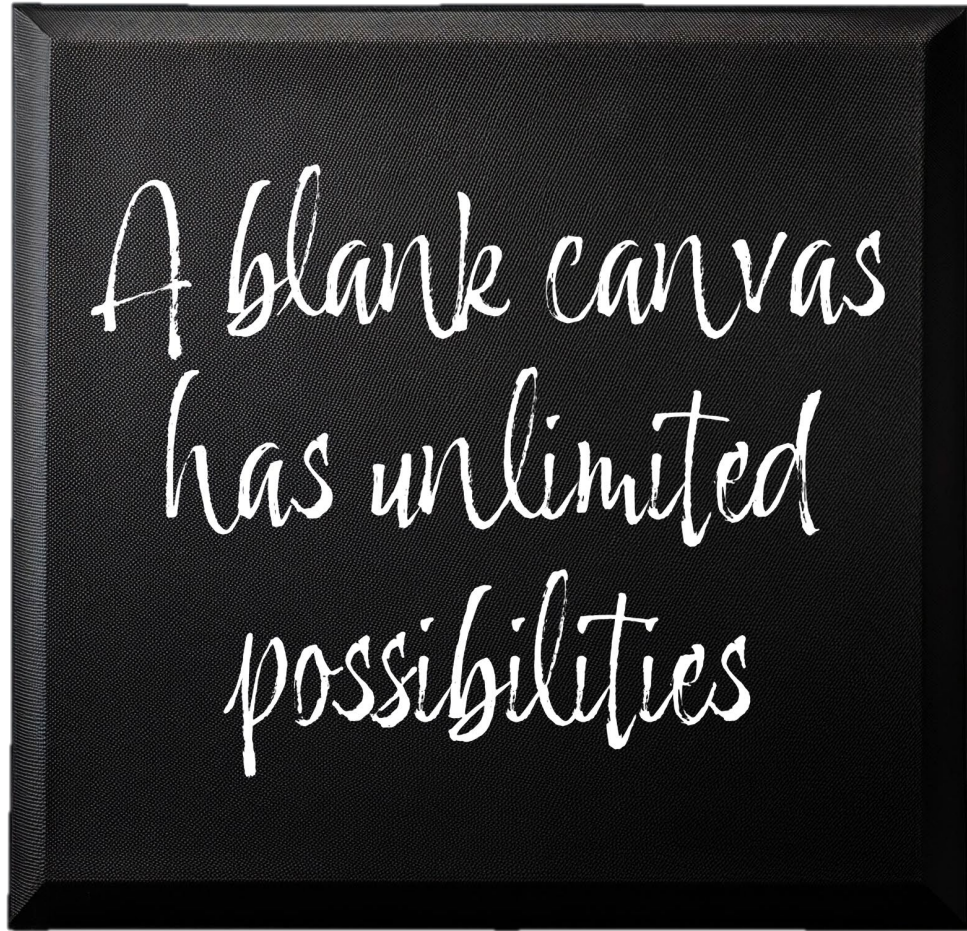
Left Ear

Bacteria, Cocci	3-4+	Numerous coccoid-shaped bacteria present
Bacteria, Rods	0-1+	Consistent with normal flora
Yeast	0-1+	Consistent with normal flora
WBC	Present	
Mites	Absent	
Diagnostic Considerations	Bacterial otitis with coccoid-shaped bacteria. The finding of numerous coccoid-shaped bacteria is 95% specific for the presence of bacterial otitis. Consider underlying causes of otitis externa. Typically these patients require longer duration of treatment or more intensive diagnostics/therapies (otic irrigation, advanced imaging to investigate potential for tumor or otitis media, foreign body presence).	
Images		

Right Ear

Bacteria, Cocci	3-4+	Numerous coccoid-shaped bacteria present
Bacteria, Rods	0-1+	Consistent with normal flora
Yeast	0-1+	Numerous yeast present
WBC	Present	
Mites	Absent	
Diagnostic Considerations	Bacterial otitis with coccoid-shaped bacteria. The finding of numerous coccoid-shaped bacteria is 95% specific for the presence of bacterial otitis. Consider underlying causes of otitis externa. Typically these patients require longer duration of treatment or more intensive diagnostics/therapies (otic irrigation, advanced imaging to investigate potential for tumor or otitis media, foreign body presence).	
Images		

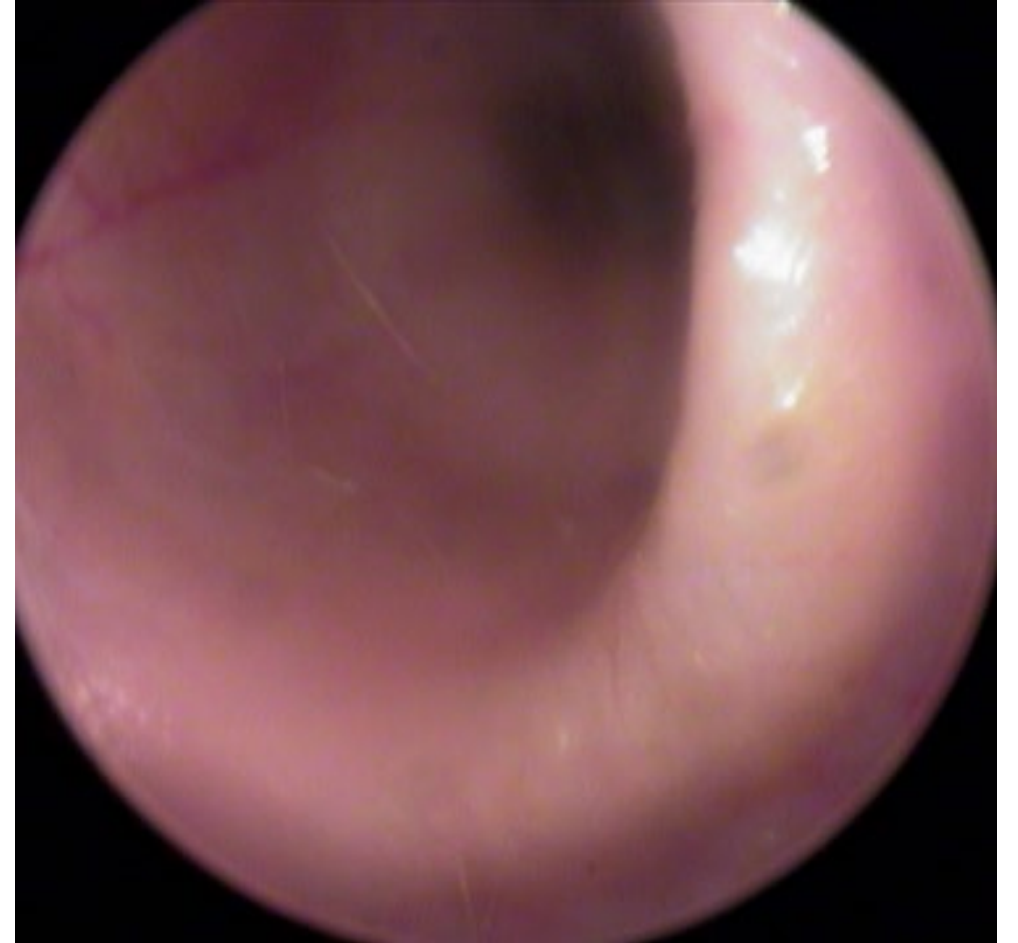Let's paint!



The Normal Ear Canal

The normal ear canal is temperature, pH, and humidity regulated.

Normal ear canals rely on the lipid content of cerumen, host defense(antimicrobial) peptides, and regulated desquamation to maintain homeostasis.



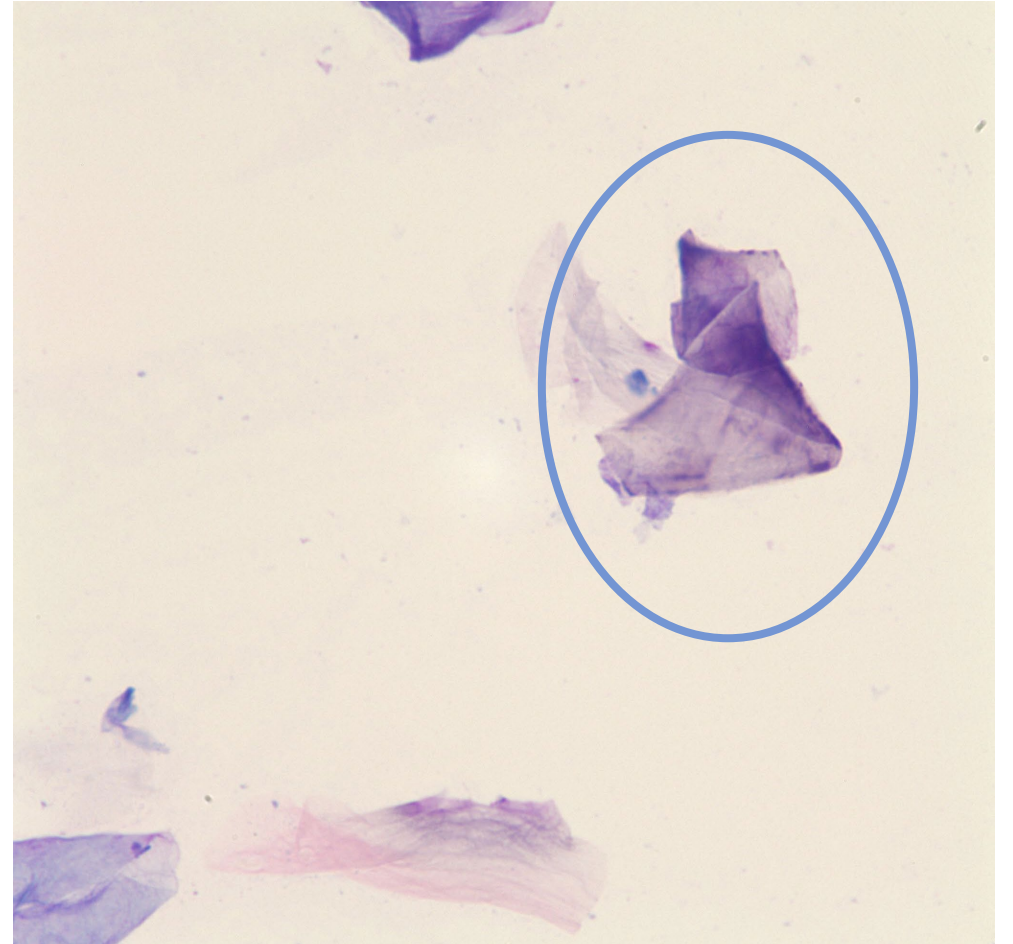
Impression Cytology of the Normal Ear

Unstained samples will appear nearly clear and slightly greasy

After staining it is still nearly clear since the lipid does not take up much stain

Few anucleated keratinocytes(squamous cells) will pick up purple stain

***A few yeast or cocci adhered to squamous cells is within the realm of normal



100x objective, few keratinocytes

Melanin Granules

Ovoid/rectangular

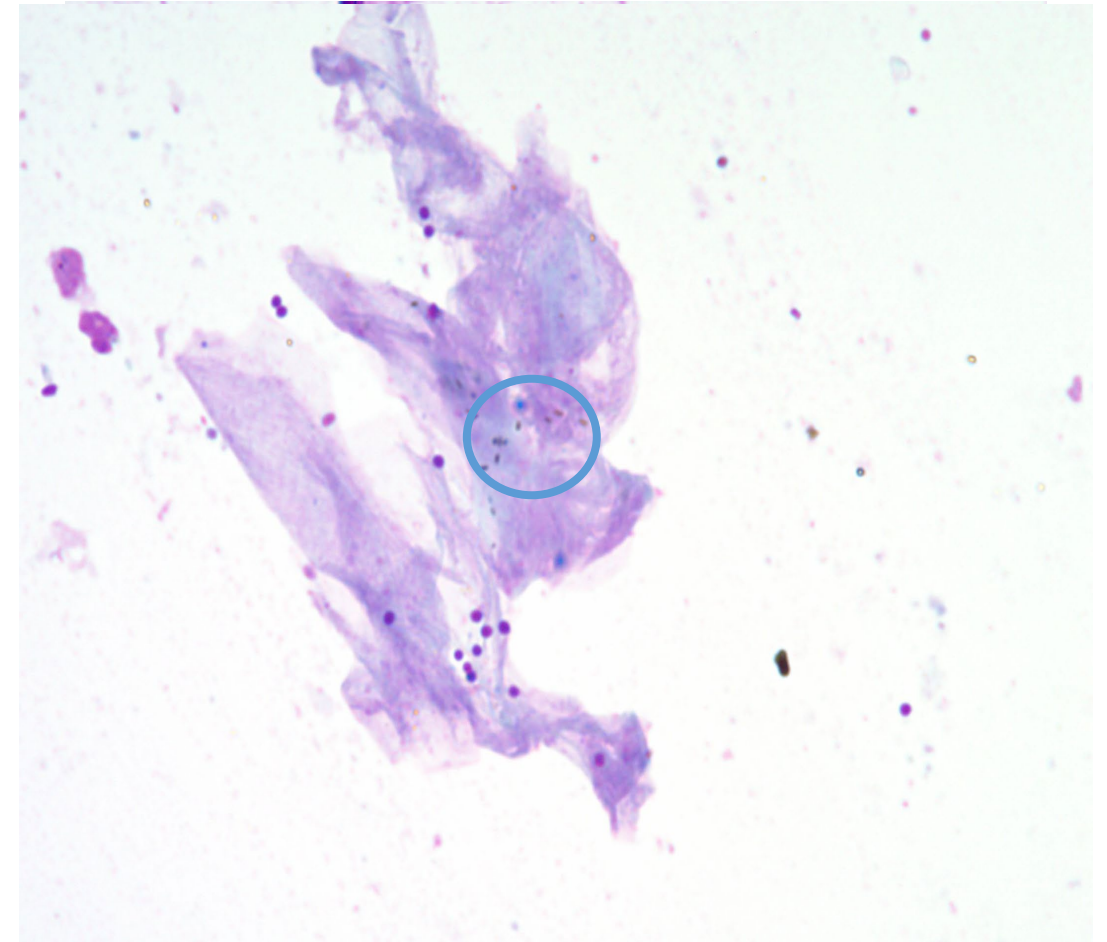
(Staphylococcal bacteria are perfect circles)

Melanin granules are brown/gold and slightly refractile

(Staphylococcal bacteria are blue/purple)

Melanin granules are always inside keratinocytes

(Staphylococcal bacteria may be adhered to keratinocytes or free in cerumen)



100x objective, melanin granules, cocci bacteria

Primary problem- What started this mess?

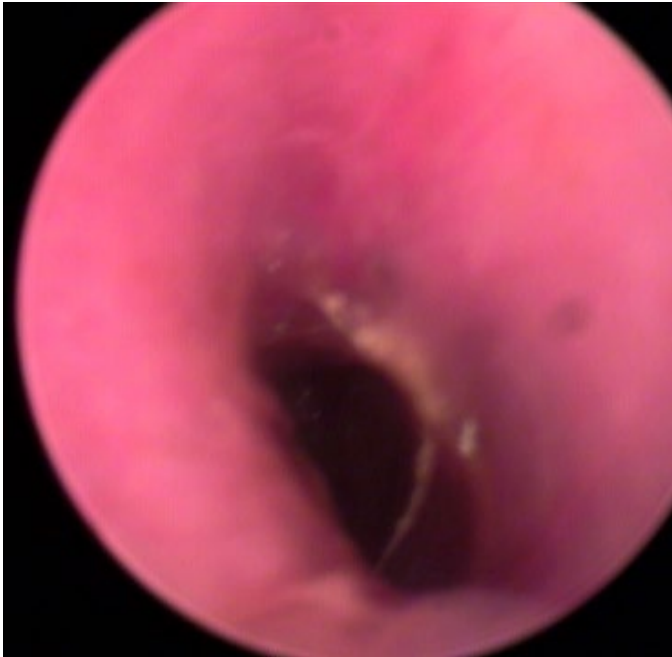Part 1

- Allergic skin and ear disease
- Endocrine disease
- Disorders of keratinization
- Ectoparasites
- Immune mediated diseases
- Foreign bodies/ Masses

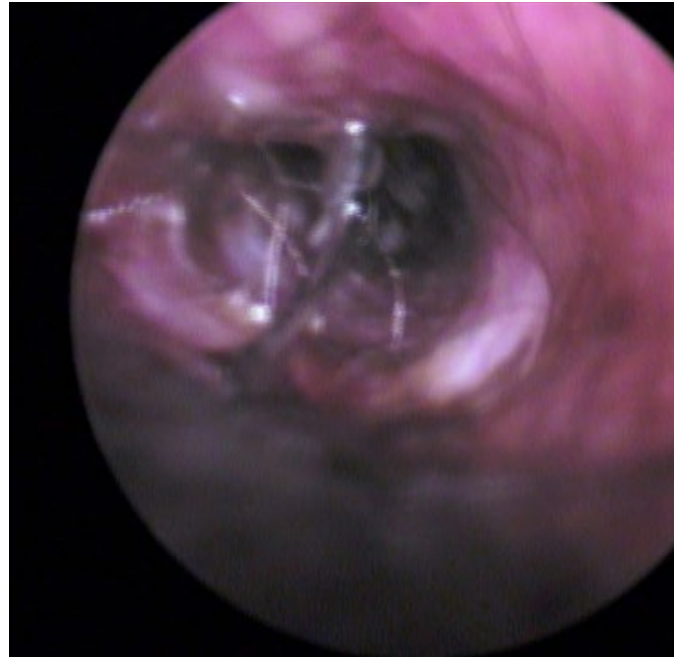
****Dogs and cats can have more than one *primary* cause for their otitis**

Allergic Otitis

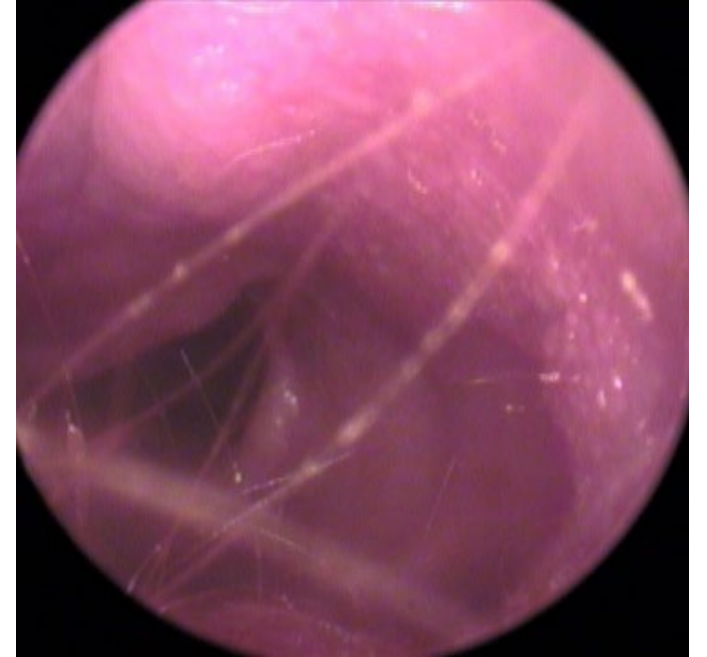“The Negative Cytology”



Erythema,
stenosis



Erythema,
stenosis, nodular
hyperplasia



Erythema, stenosis,
epithelial
hyperplasia

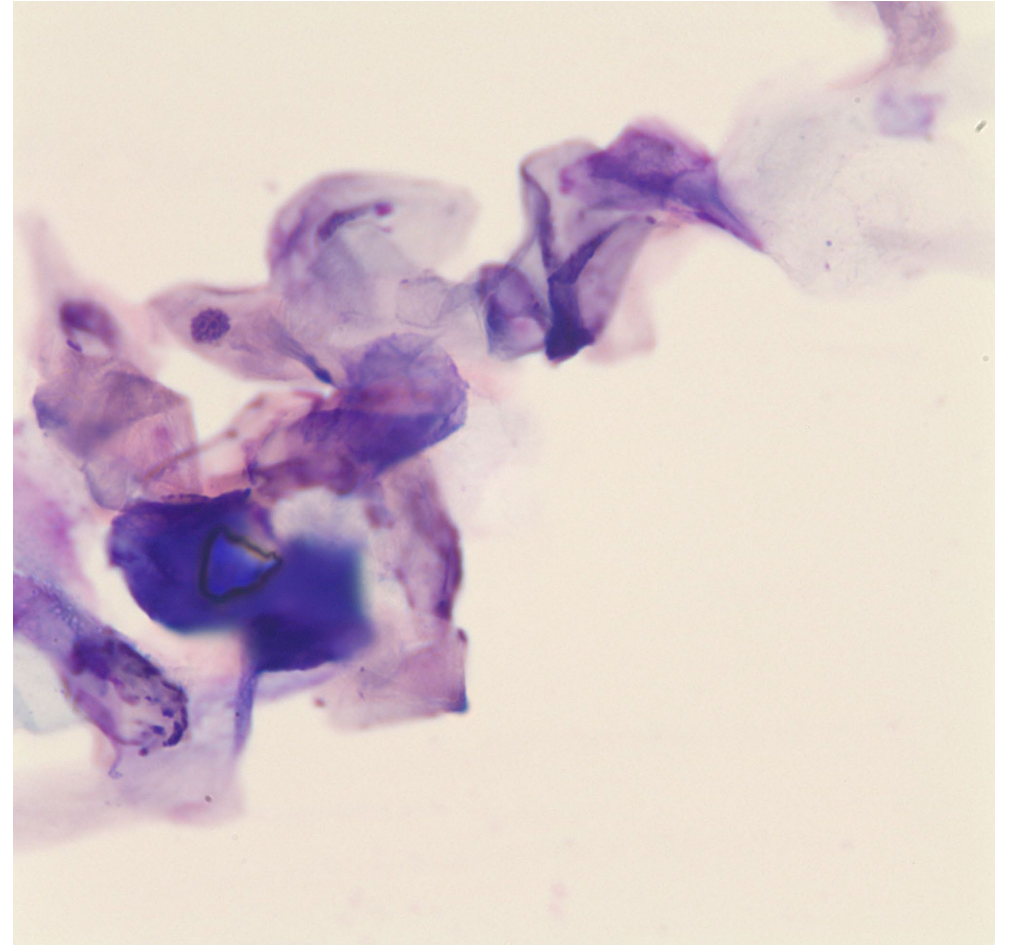
Inflamed ear canal

‘Nothing to see here’

Increased number of keratinocytes
- anucleate and nucleated keratinocytes

The cerumen has a lower lipid content
-potential for more blue/purple stain uptake

**More chronic cases may have low numbers neutrophils or proteinaceous debris



Variably stained
keratinocytes

Allergic Otitis-flea, food, atopy (environmental)

Diagnosis

- Is the patient on excellent year-round flea/ectoparasite control?
- Are the clinical signs(otitis, body itch etc) year-round, seasonal, sporadic?
- If ANY signs of itch are non seasonal, has a strict prescription diet trial been performed?
- Dogs/Cats with no response to prescription diet trial while on flea/ectoparasite control likely have environmental based allergy.

Treatment

Flea allergy = year-round treatment for affected pet and house mates

Food allergy = continue diet that does not lead to flares

Allergic Otitis

Systemic Treatment

Corticosteroids-Best for acute flares and management of nodular hyperplasia

Modified Cyclosporine- Good for management of chronic inflammation along with ototopical

Oclacitinib (or ilunocitinib) – mixed response for management of chronic inflammation along with ototopical

Ototopical Treatment

Higher Potency Corticosteroids

-Fluocinolone acetonide 0.01 % and DMSO 60%

-Hydrocortisone aceponate

-Mometasone

-Dexamethasone SP 4mg/ml

Lower Potency corticosteroids

-Burrows Solution with Hydrocortisone

-acetic acid 1%, 0.15% ketoconazole, 1% hydrocortisone flush

Keratinaceous/Ceruminous otitis

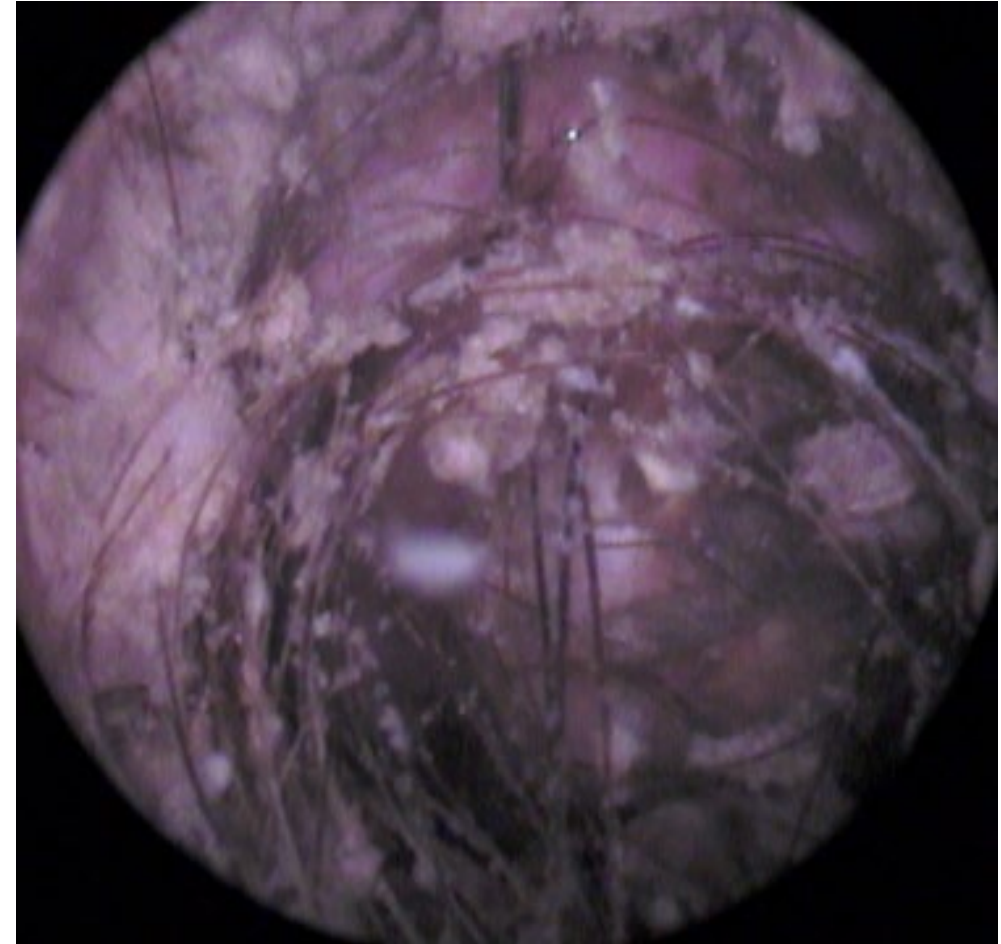
Increase in keratinocytes without inflammatory cells

Keratinization disorders

- Vitamin A-responsive Dermatitis (Cocker Spaniels)
- Primary seborrhea
- Sebaceous Adenitis (Poodles, Akitas, Vizsla)

Endocrine

- Hypothyroidism
- Hyperadrenocorticism



Thick debris admixed with hair

Keratinaceous/Ceruminous Otitis

Diagnosis

- The clinical signs do not support allergic skin and ear disease OR allergic disease is well controlled
- Endocrine testing performed when the patient is not inflamed or infected is consistent with hypothyroidism or hyperadrenocorticism
- Breed, clinical signs +/- skin biopsy have diagnosed sebaceous adenitis or Vit A responsive dermatosis

Treatment

Keep the pH of the ear canal acidic

- Acetic acid based branded flushes
- 1:1 water/ white vinegar(5-6%)

Soften/break down waxy accumulations

- Phytosphingosine
- Propylene glycol (sebaceous adenitis)
- Squalene (severe build up of debris)

Secondary and Predisposing Factors

Part 2

- ***Secondary infectious otitis externa*** is most often caused by Malassezia yeast, cocci bacteria(Staphylococcus, Streptococcus), and rod bacteria (Pseudomonas, Proteus, Corynebacterium)
- ***Noninfectious secondary factors*** include Dry overcleaning (either with dry cotton or gauze), wet overcleaning (water-based cleaners), ear canal irritants(low pH products, alcohol)
- ***Predisposing factors*** such as hair type/amount in canals, pendulous ears, humidity, and water exposure increase the chance of ***secondary infectious otitis externa***

***Malassezia* Yeast**

Malassezia pachydermatis

Opportunistic pathogen that is part of the normal flora

Bowling pin, snowman, peanut shaped when budding

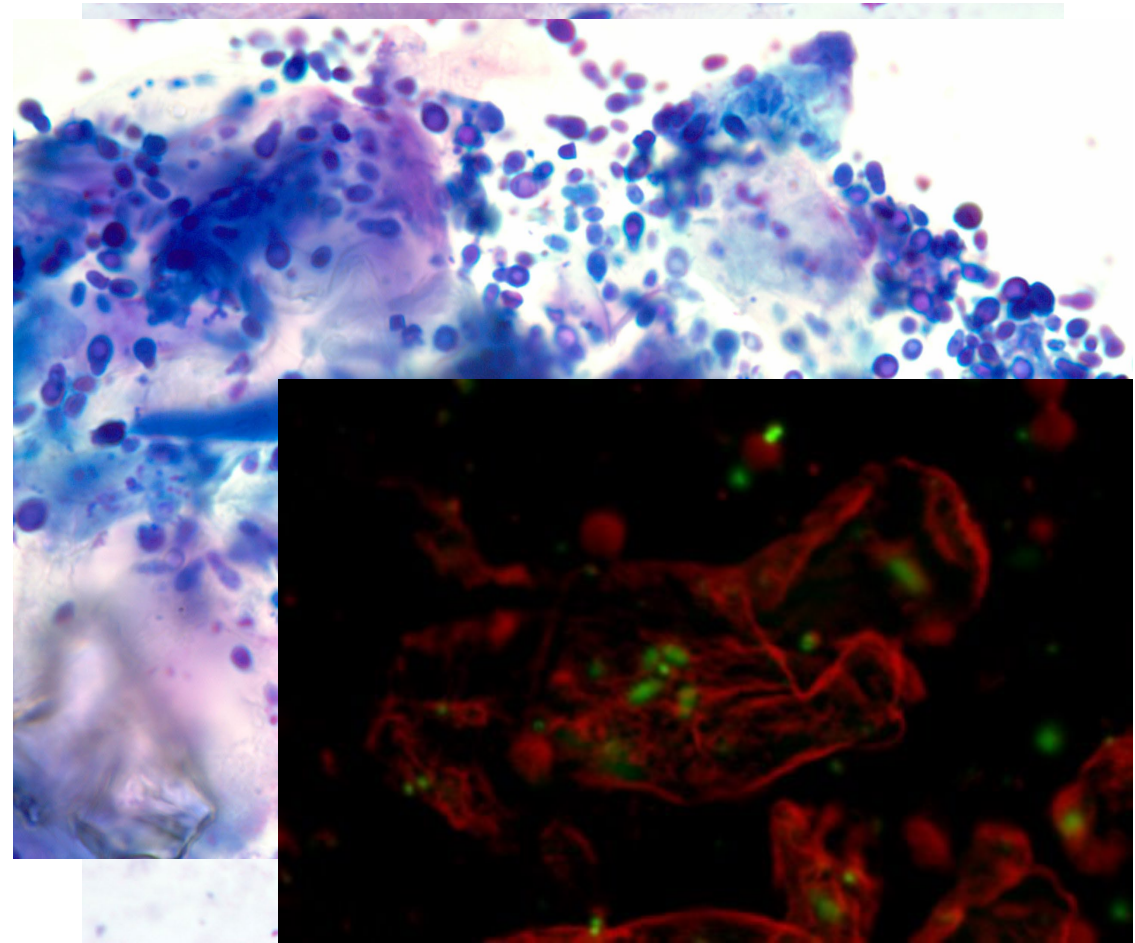
Stain deep blue/purple with Diff Quick®

Treatment:

Terbinafine

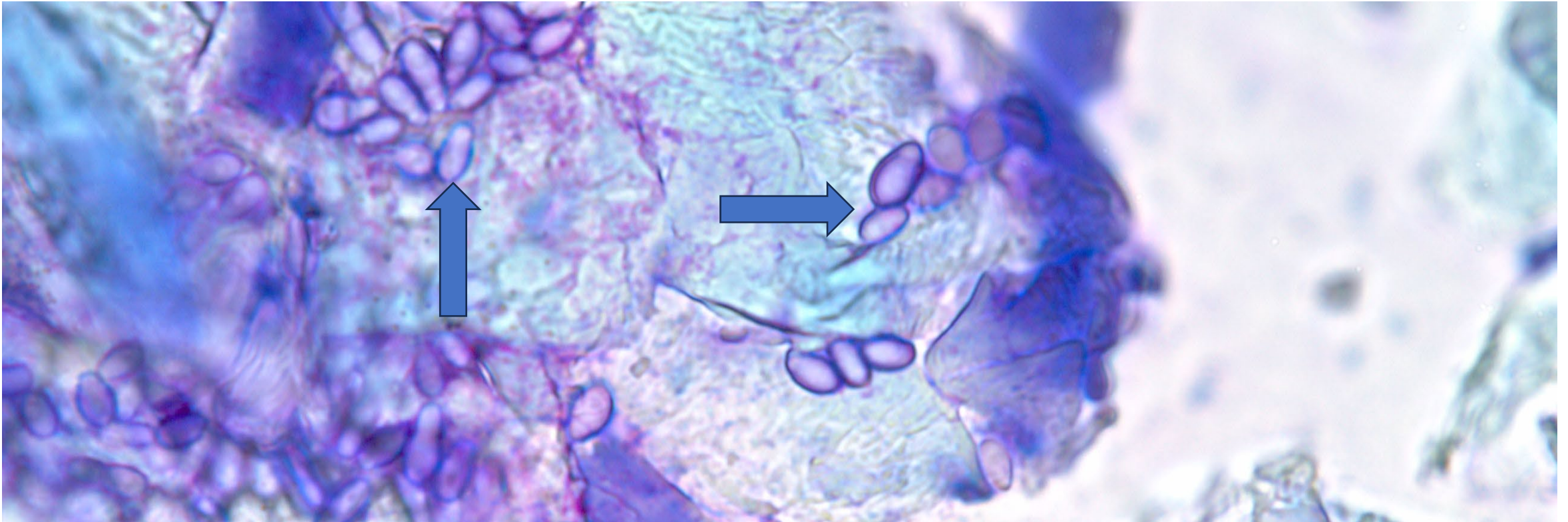
Azoles (Posaconazole, thiobendazole, miconazole, clotrimazole)

Corticosteroid Ototopical



Boo....it's a ghost (yeast)

Malassezia pachydermatis



Cocci Bacteria

Staphylococcus pseudintermedius

Opportunistic pathogen that is part of the normal flora

Deeply blue/purple perfect circles when stained with Diff Quick®

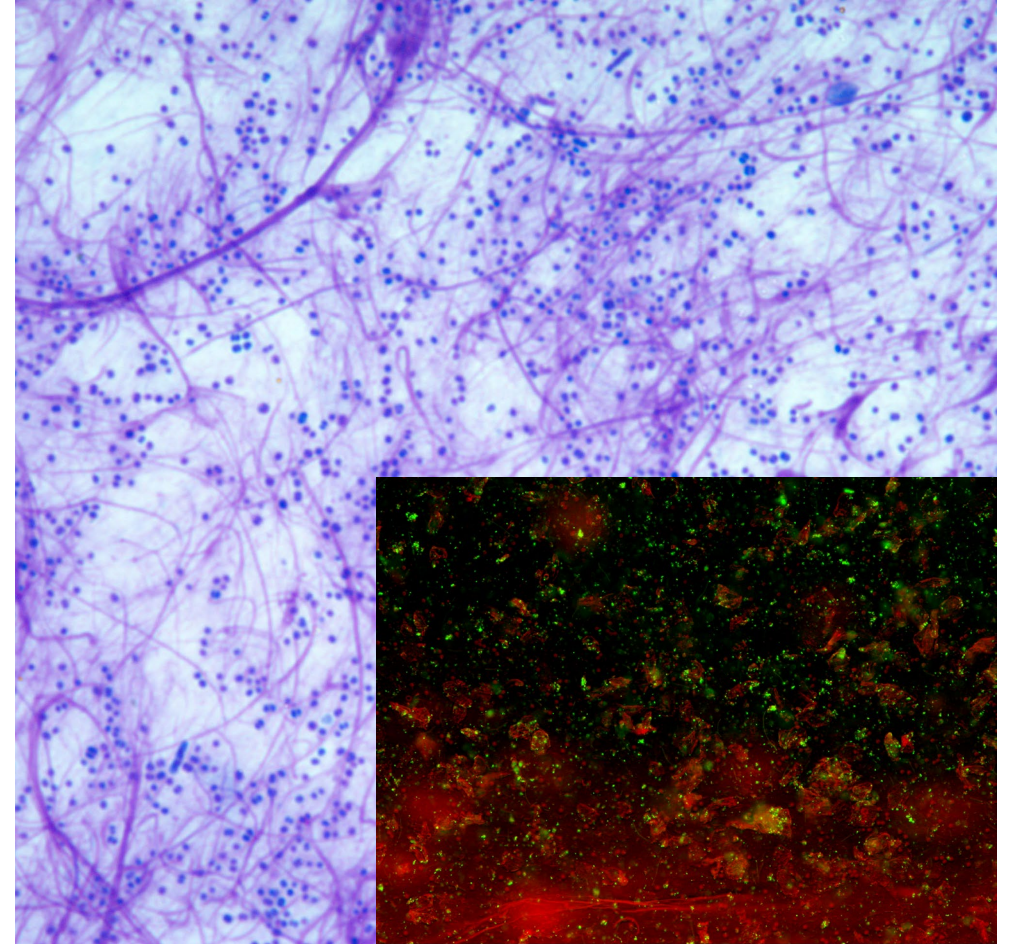
Treatment:

Aminoglycoside (gentamicin, neomycin)

Florfenicol

+/-Fluroquinolone (enrofloxacin)

Corticosteroid Ototopical



Rod Shaped bacteria

Pseudomonas aeruginosa

- Pseudomonas* and other rod shaped bacteria are never 'normal' on otic cytology
- Deeply blue/purple rods
- Pseudomonas* requires inflammation + predisposing factor (increased humidity, increased pH) to overgrow
- Rod shaped otitis is more common in ears that have chronic changes from previous inflammatory and infectious (cocci, yeast) insults.

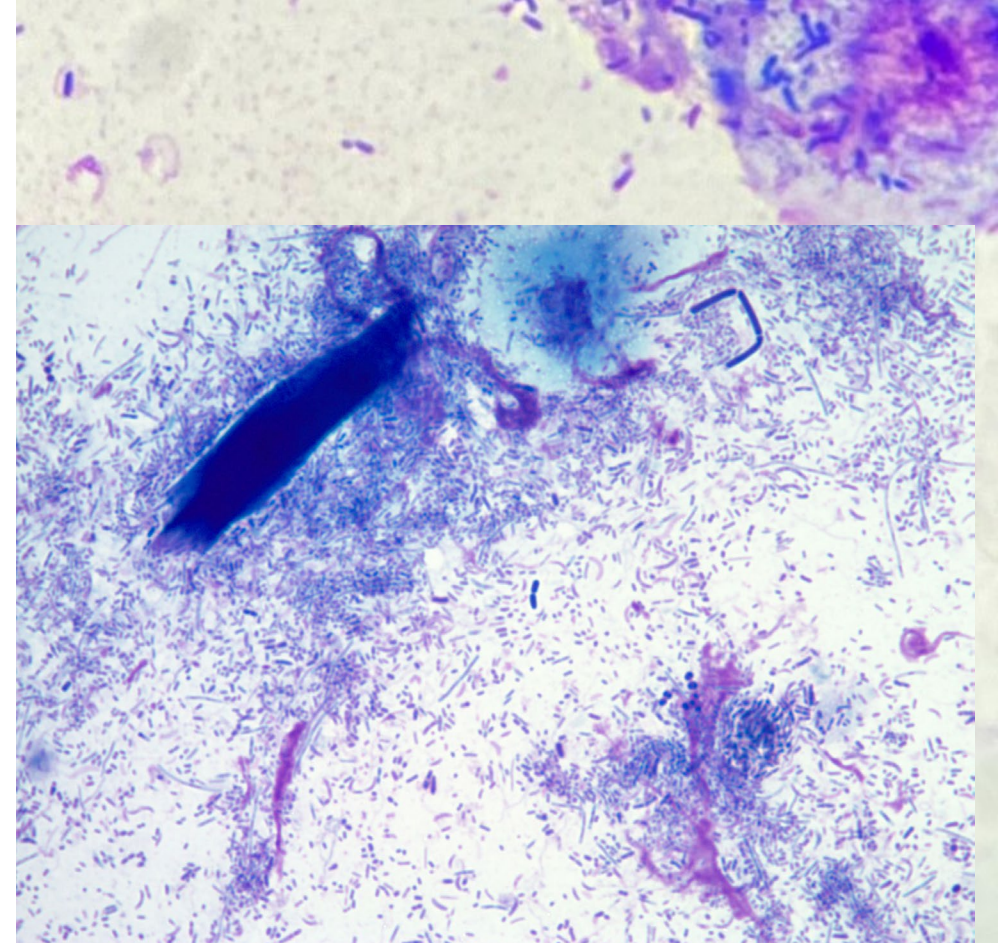
Treatment:

Polymixin B

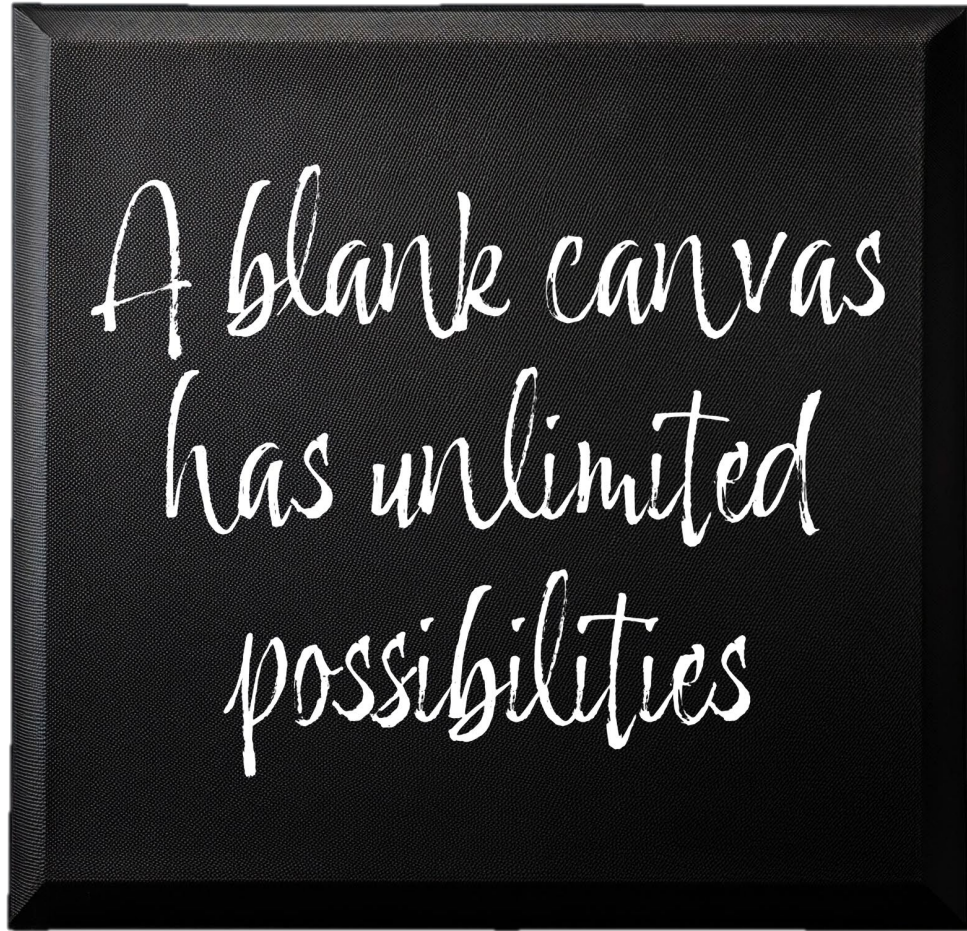
Fluoroquinolone (enrofloxacin)

Silver Sulfadiazine

Aminoglycoside (Amikacin)



Let's paint!



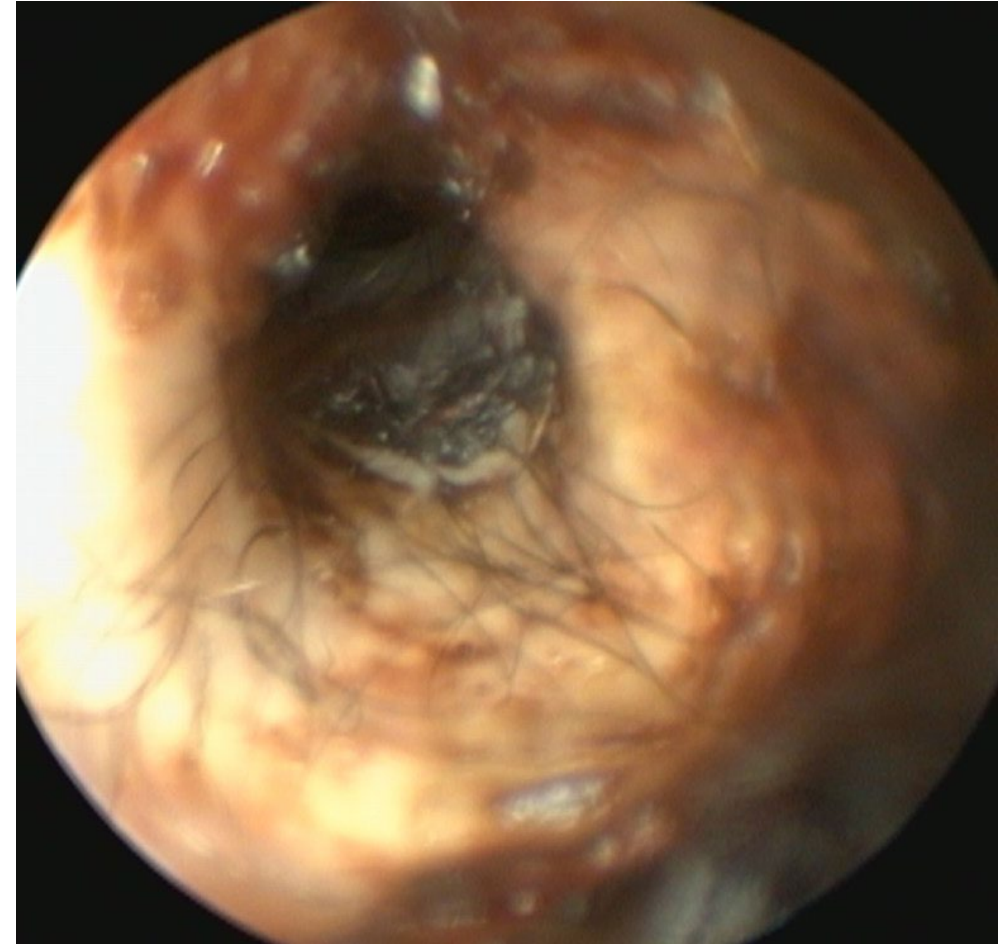
Case Presentation -2 year old GSD Mix

First Time Offender

HX: Went swimming in the pond twice last weekend and is now shaking head.

No prior ear infection, mild pedal pruritus in the spring and summer, monthly isoxazoline flea/tick control. Presumed healthy animal.

PE: No skin erythema, no ectoparasites, BCS 5/9
Both ear canals similarly affected. TM are intact



Minimal erythema, moderate
dark brown waxy debris

Case Presentation- 2 year old GSD Mix

First Time Offender

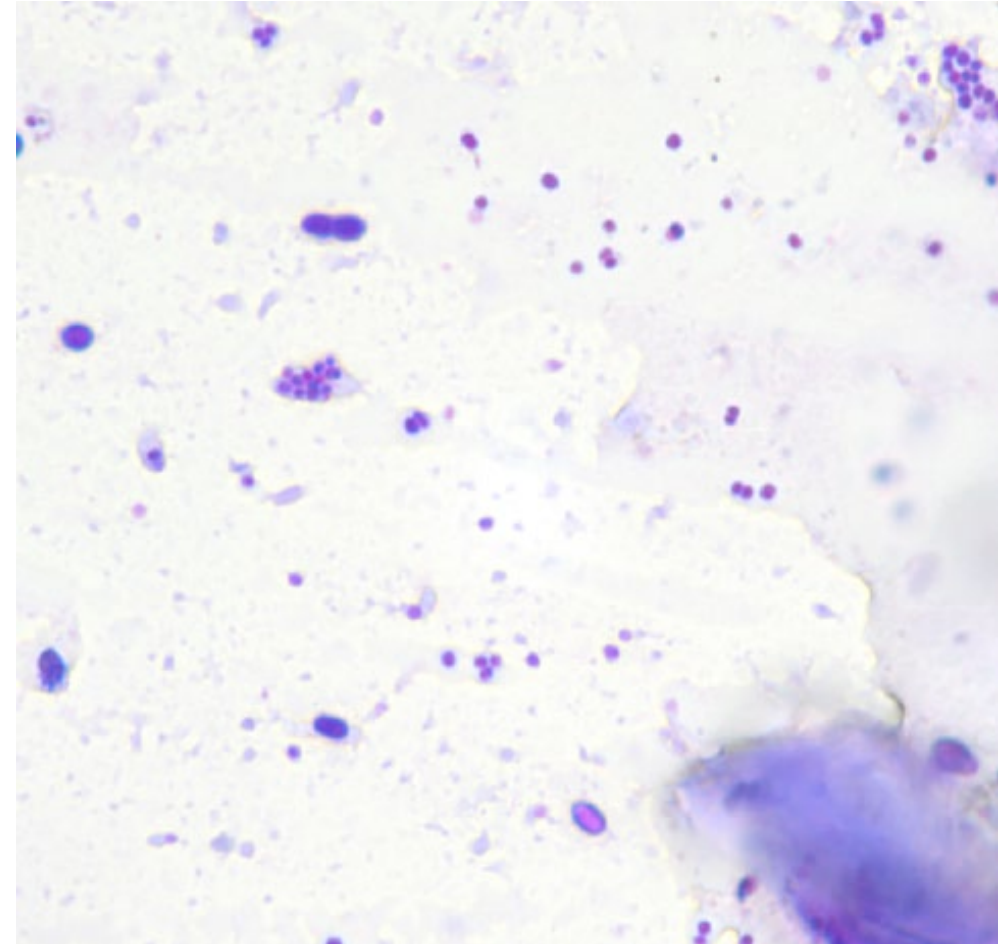
Cytology results have evidence cocci bacteria and *Malassezia* overgrowth

Primary Problem: Allergic skin and ear disease (minimal to mild)

Predisposing factor: Wet ear canals from swimming

Secondary factor: cocci bacteria and *Malassezia* overgrowth

Treatment: Corticosteroid ototopical and cleanser OR leave in terbinafine + antibacterial ototopical OR azole ototopical + antibacterial ototopical +/- cleanser



Moderate cocci and fewer yeast

First Time Offender

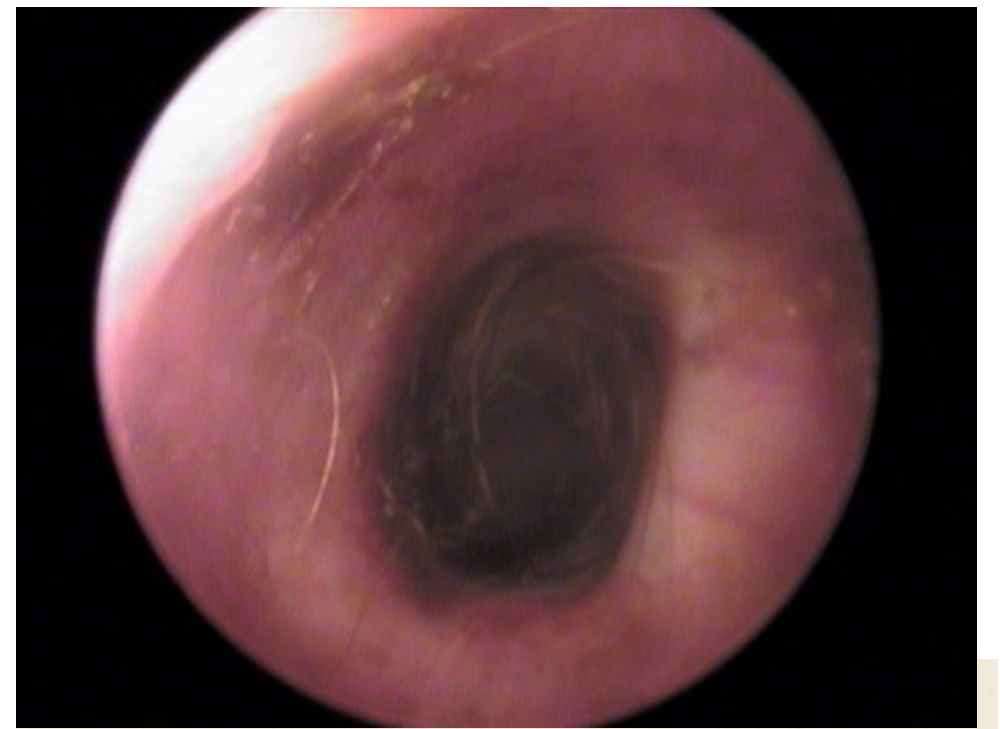
Recheck 2 weeks later

HX: Applied medications as directed, head shaking has resolved

PE: No skin erythema, no ectoparasites, BCS 5/9

Ear canals have minimal erythema, but otherwise normal on otoscopic examination

Treatment: monitor for new clinical signs, cerumenolytic and antimicrobial cleanser after swimming



Few anucleate
keratinocytes

Case Presentation- 2 year old GSD Mix

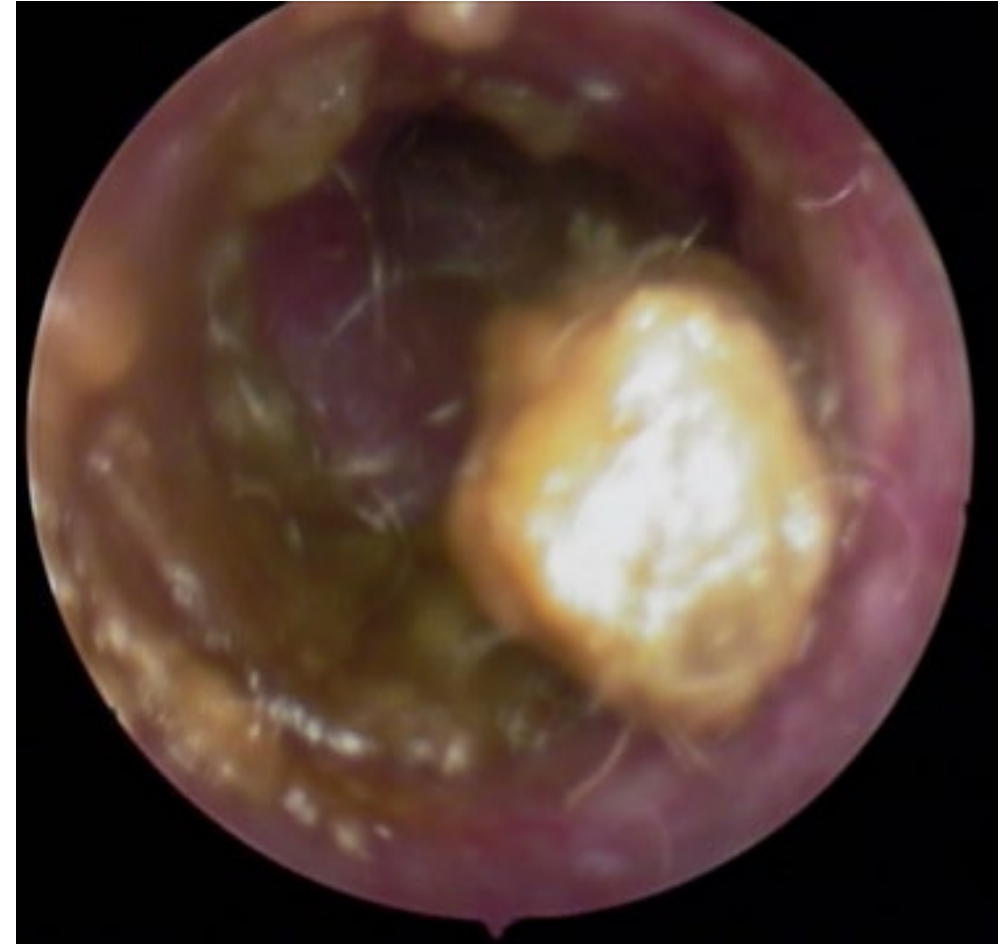Repeat Offender

HX: Went swimming in the pond twice last weekend and is now shaking head.

4 prior ear infections, moderate spring-fall pruritus of paws and trunk, monthly isoxazoline flea/tick control.

PE: Salivary staining on paws, excoriations on the axilla with occasional papules on axilla and inguinal region , no ectoparasites, BCS 5/9

Both ear canals similarly affected. TM are intact



Erythema, epithelial hyperplasia,
ceruminous debris, ceruminolith

Case Presentation – 2 year old GSD Mix

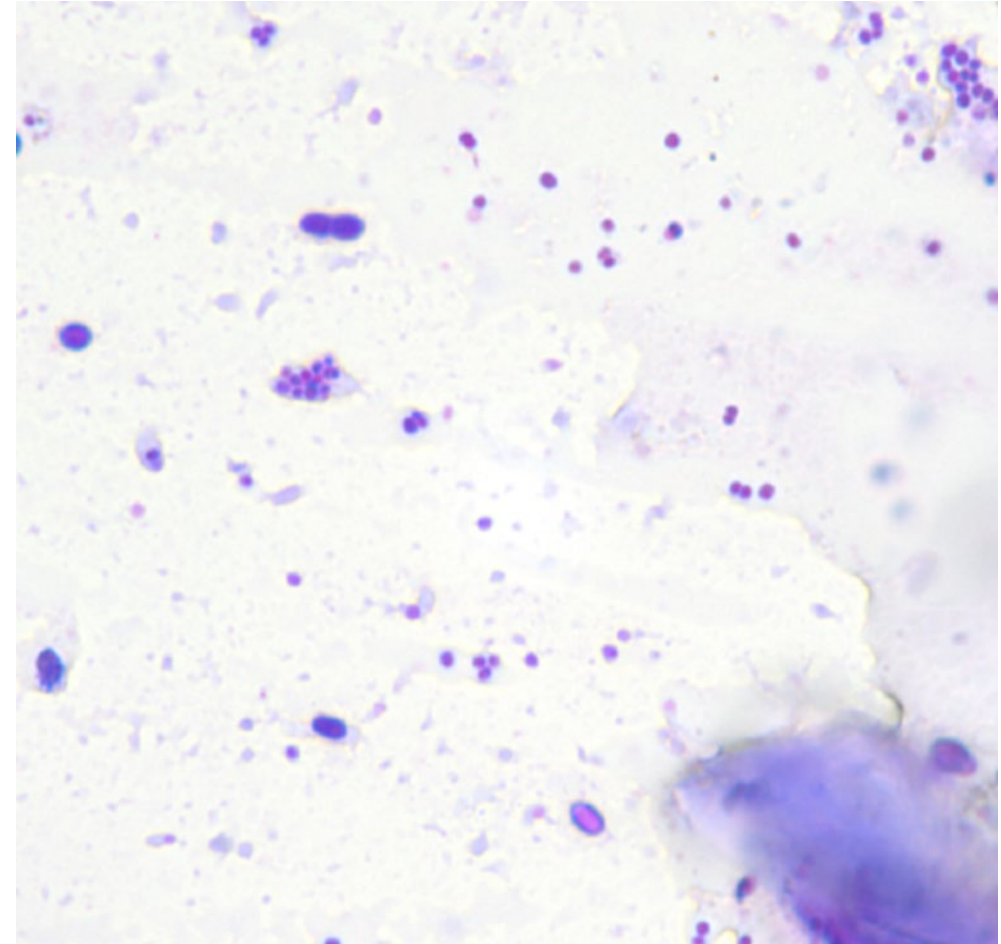
Repeat Offender

Cytology results have evidence cocci bacteria and *Malassezia* overgrowth

Primary Problem: Allergic skin and ear disease (moderate, relapsing)

Predisposing factor: Wet ear canals from swimming

Secondary factor: cocci bacteria and *Malassezia* overgrowth



Moderate cocci and
fewer yeast

Case Presentation- 2 year old GSD Mix

Treatment

Topical Plan

- Corticosteroid ototopical and cerumenolytic cleanser

OR

- azole antifungal ototopical + topical antibiotic and ceruminolytic cleanser

OR

- terbinafine ototopical + topical antibiotic and ceruminolytic cleanser

Systemic Plan

Oral corticosteroid 0.5-1mg/kg per day until resolution of inflammatory changes, then taper

*** modified cyclosporine OR oclacitinib would only be chosen if there was a significant contraindication for a corticosteroid.

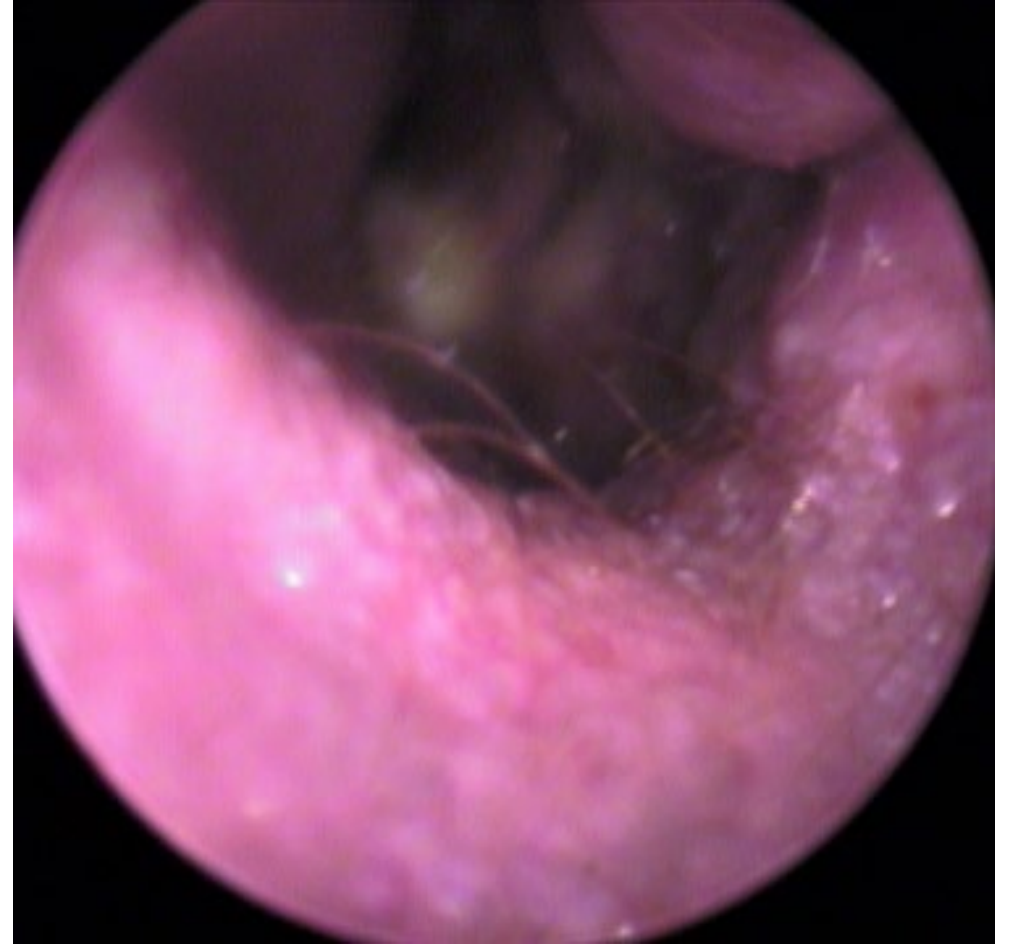Repeat Offender- 2 year old GSD Mix

Recheck 2 weeks later

HX: Owner administered medications as directed, head shaking is improved but not resolved

PE: Reduced salivary staining on paws, papules and excoriations resolved.

Ear examination shows minimal debris with erythematous slightly irregular ear canals and focal stenosis



Erythema, epithelial and glandular hyperplasia, mild stenosis

Case Presentation -2 year old GSD Mix

Maintenance Plan

Topical Plan

Otological steroid daily until inflammation resolves +/- a few times per week longer term

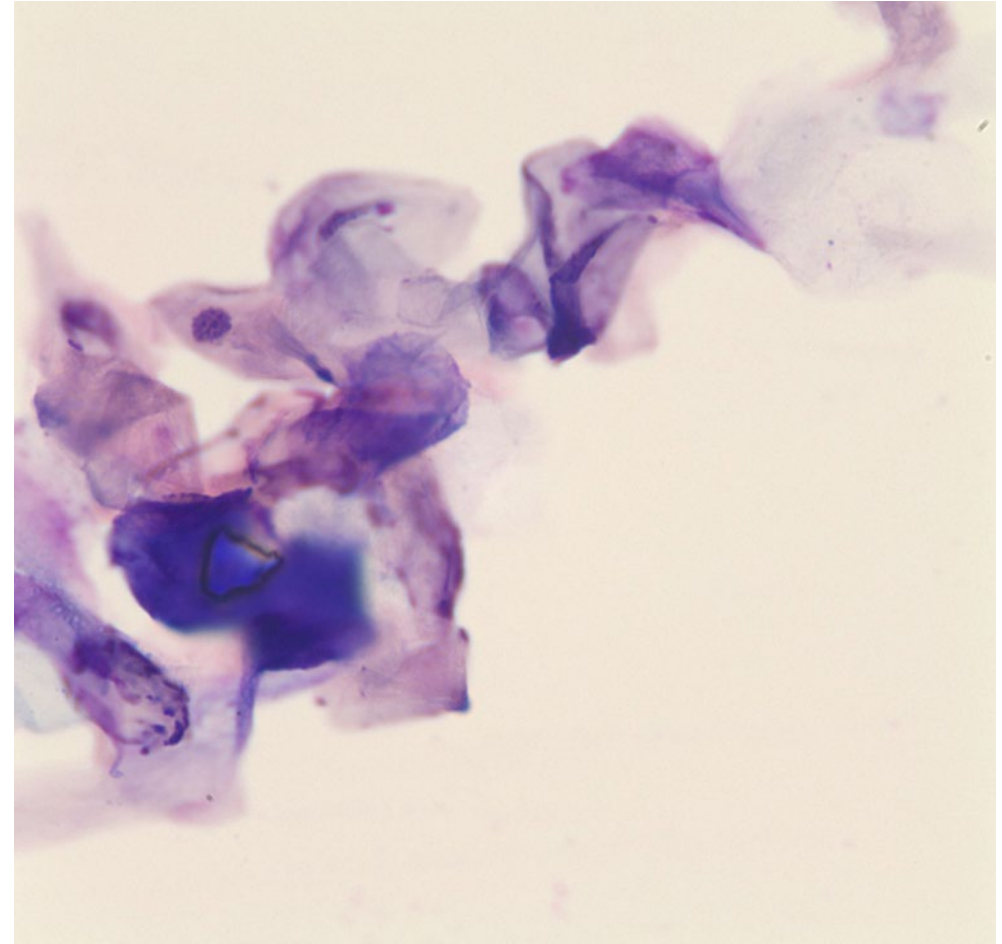
Ceruminolytic and antimicrobial flush 1-2 times per week and after swimming

Systemic Plan

Modified cyclosporine

Oclacitinib or Ilunocitinib

Allergy specific immunotherapy (+ CsA or oclacitinib)



Variably stained keratinocytes

Ear Flushing and Otitis

Ceruminous

Oil based cleansers

Alcohol based cleansers

Purulent

Water based cleanser

Detergent based cleanser

Antimicrobial

Low pH products including
acetic acid based

Isopropyl alcohol

Chlorhexidine

Hypochlorous acid

Adjunctive Antimicrobial

Triz- EDTA

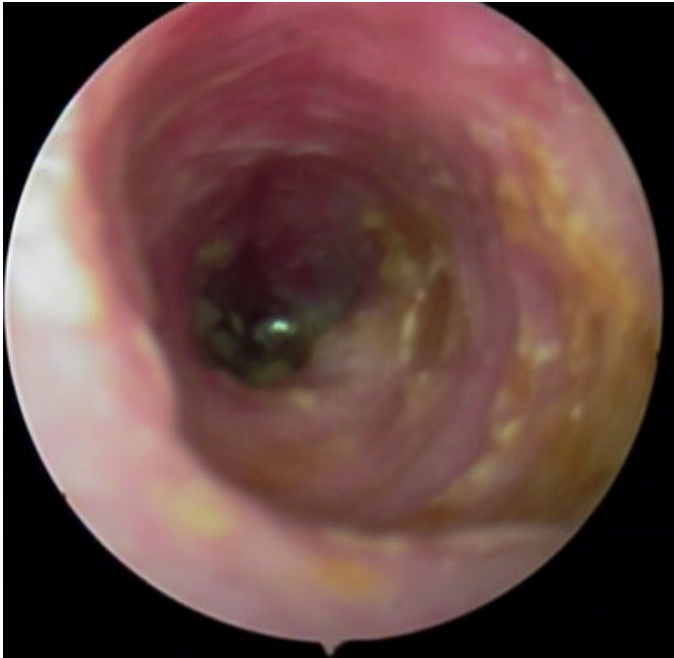Monosaccharides,
polysacaccharides

Now let's make it even more complicated

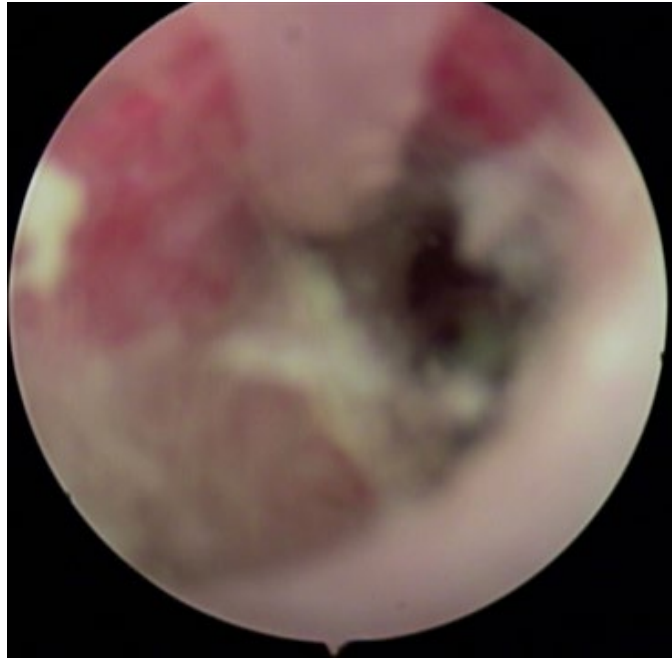
Perpetuating factors- Part 3

- Ulcerative ear canals (edema, lack of normal glandular function)
- Calcification
- Nodular hyperplasia
- Worsening Stenosis
- Otitis media +/- osteomyelitis

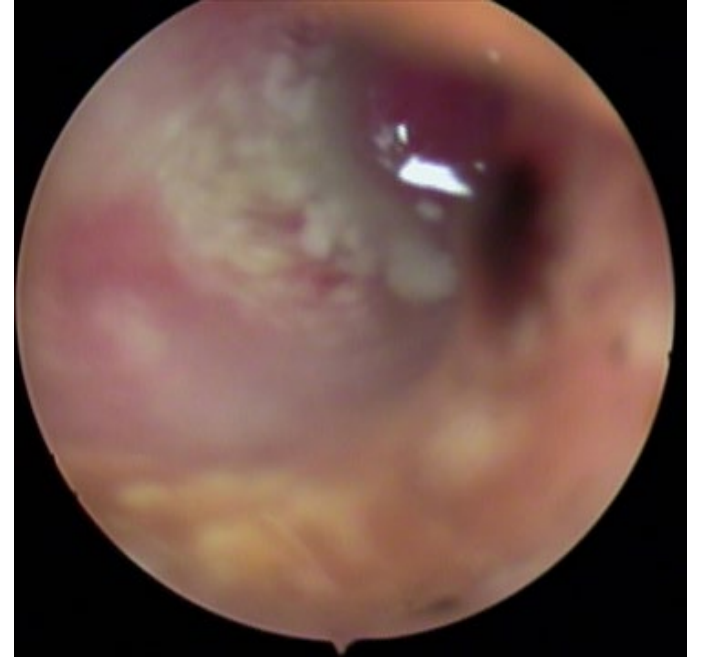Perpetuating factor: Ulcerated ear canals



Ceruminous/seborrheic
to purulent discharge

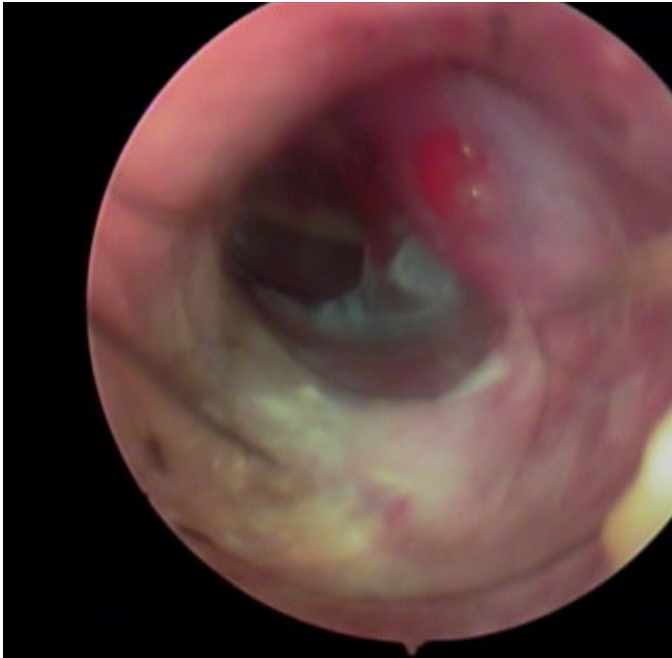


Purulent discharge

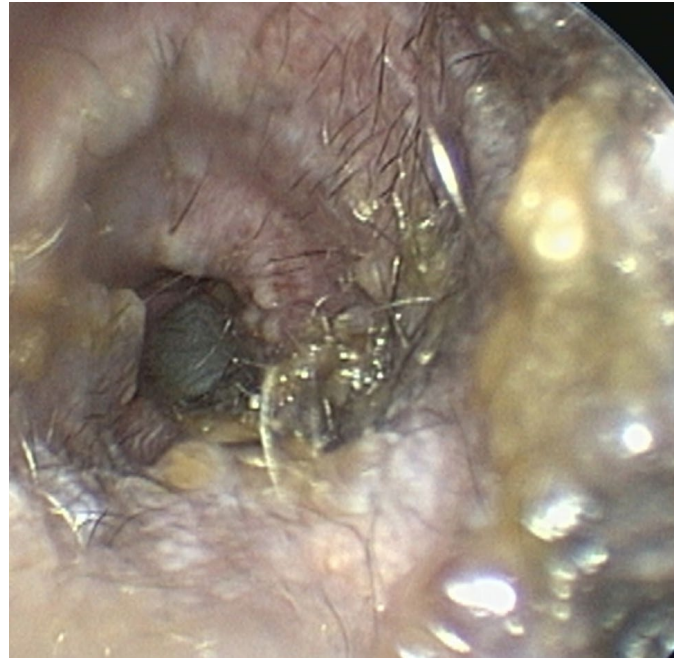


Thick and slimy purulent
discharge, probable
biofilm

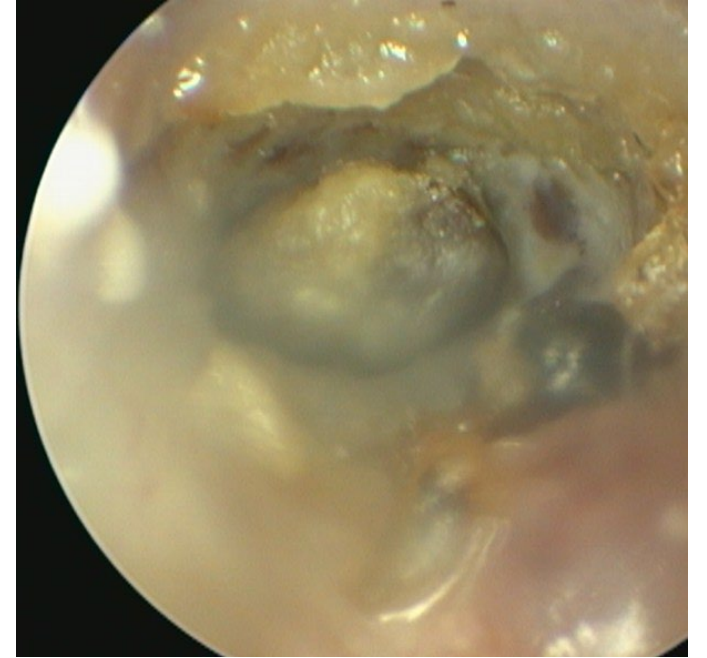Perpetuating Factors



Otitis Media,
ulcerations of canal



Nodular glandular and
epithelial hyperplasia,
moderate stenosis



Heavy debris admixed
with ear packing
material, ceruminoloth

Inflammatory Cells

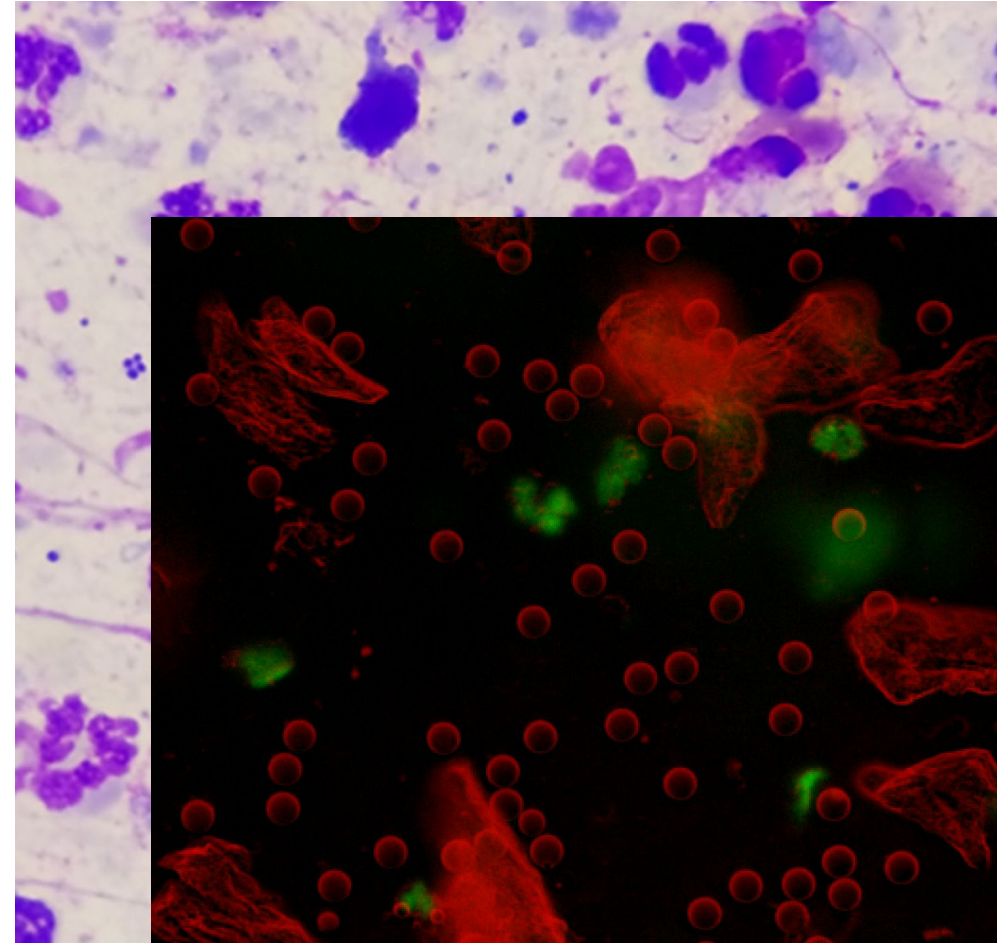
Neutrophils

Inflammatory cells are not present in acute otitis

Chronic otitis externa, especially with secondary bacterial infection will have neutrophils and occasionally macrophages

Neutrophils and neutrophilic streaming may be an indicator of otitis media

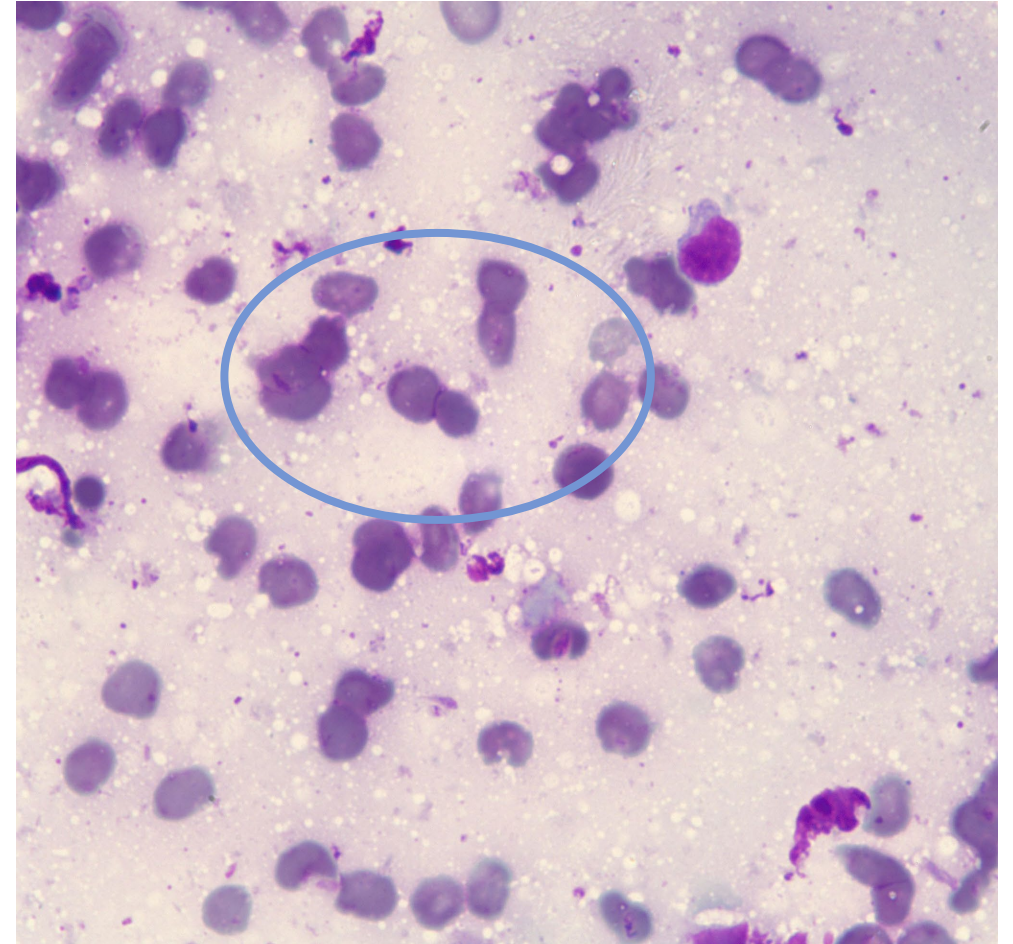
Neutrophils and macrophages may be present in cases of polyp/tumor in the ear canal



Red Blood Cells

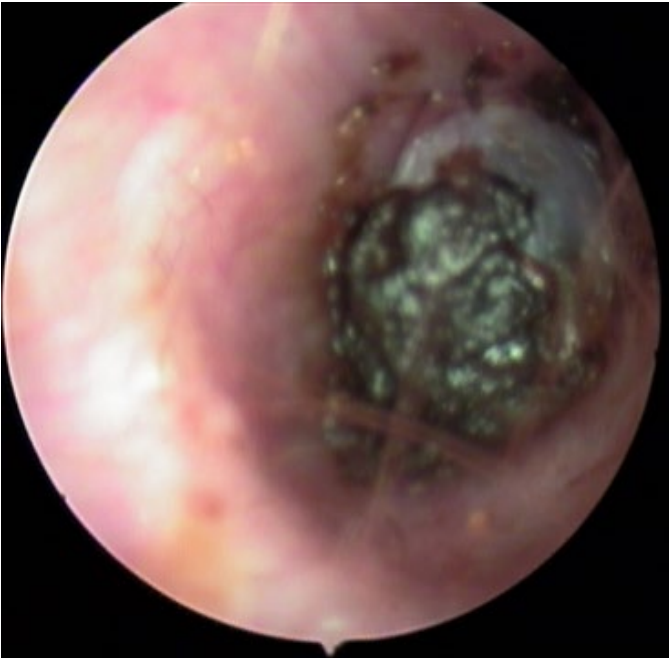RBC's may be present in ulcerated ear canals

RBC's may be present in cases of polyp/masses

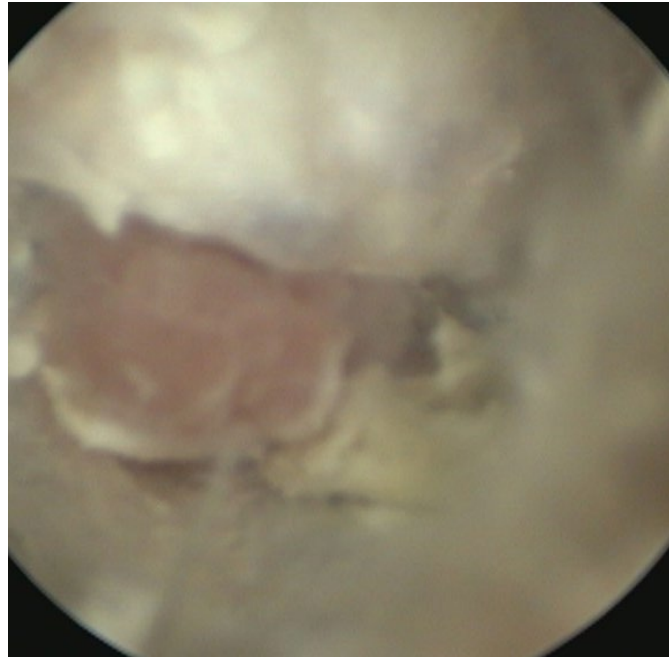


Referral cases- Older Feline and ear mass

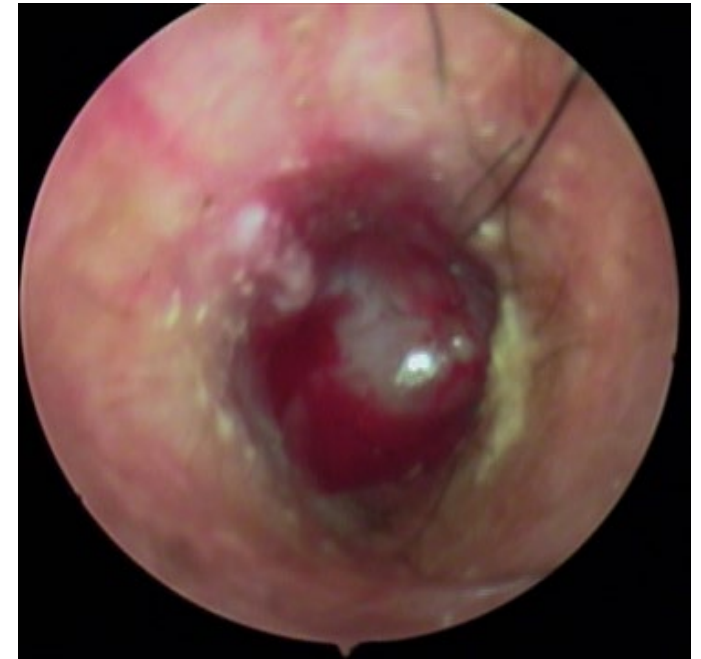Recurrent otitis externa



Mass covered by
ceruminous debris



Erythematous mass
surrounded by keratin
debris



Bleeding otic mass

Referral cases- Older Feline and ear mass

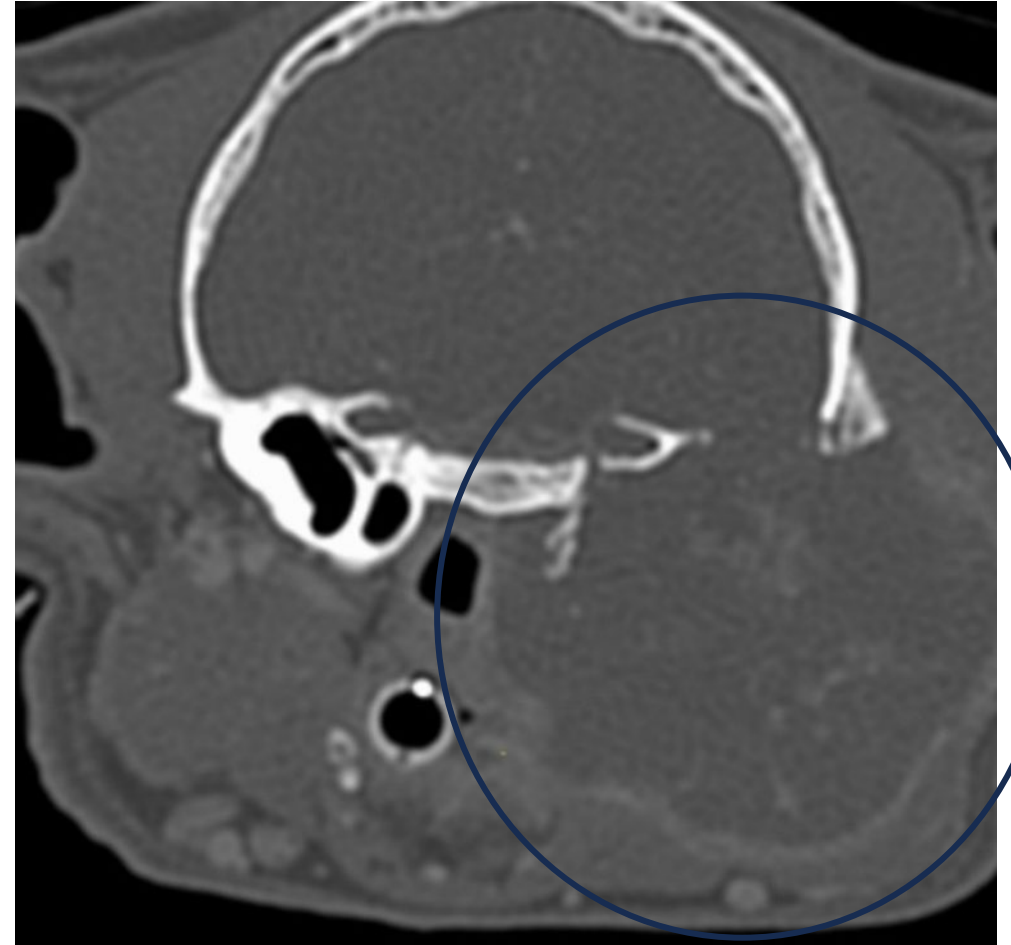
Malignant Neoplasia

Early referral and CT imaging is recommended if there is concern for a mass

Malignant tumor types include: ceruminous adenocarcinoma and squamous cell carcinoma

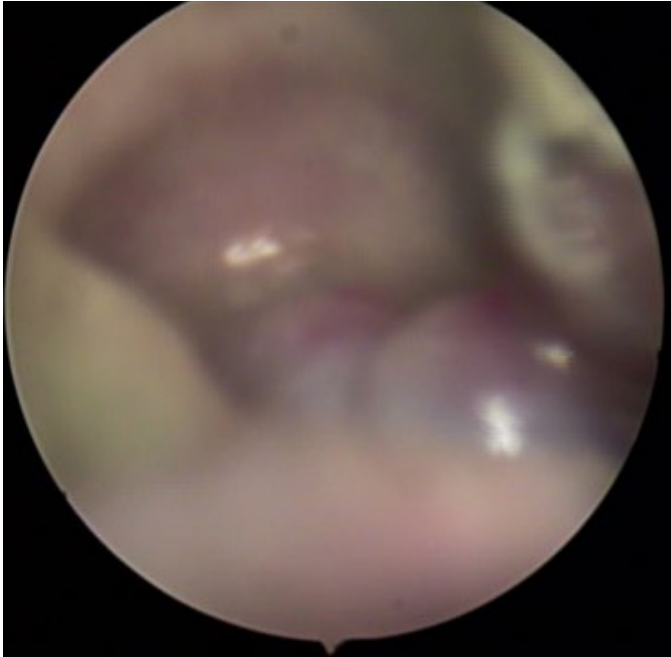Without gross extension beyond the canal, total ear canal ablation +/- radiation therapy

With extension outside the ear canal, palliative care +/- radiation therapy are remaining options

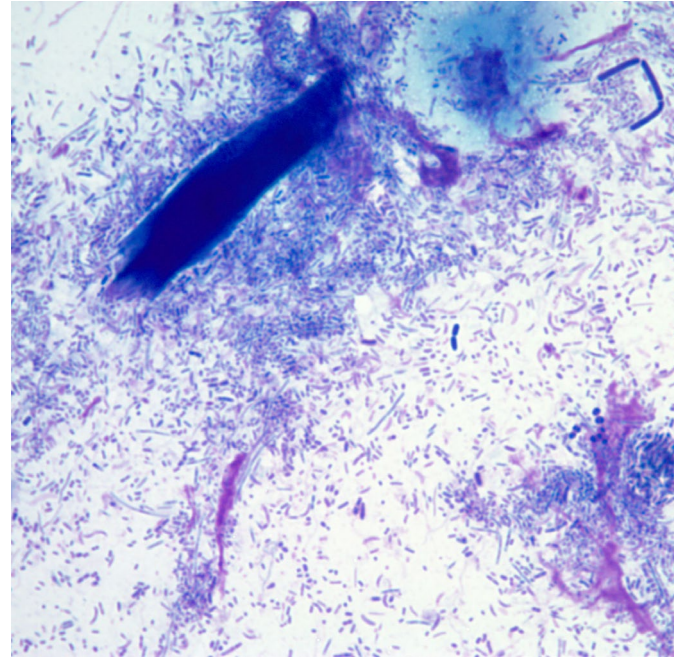


Expansive and lytic malignant mass

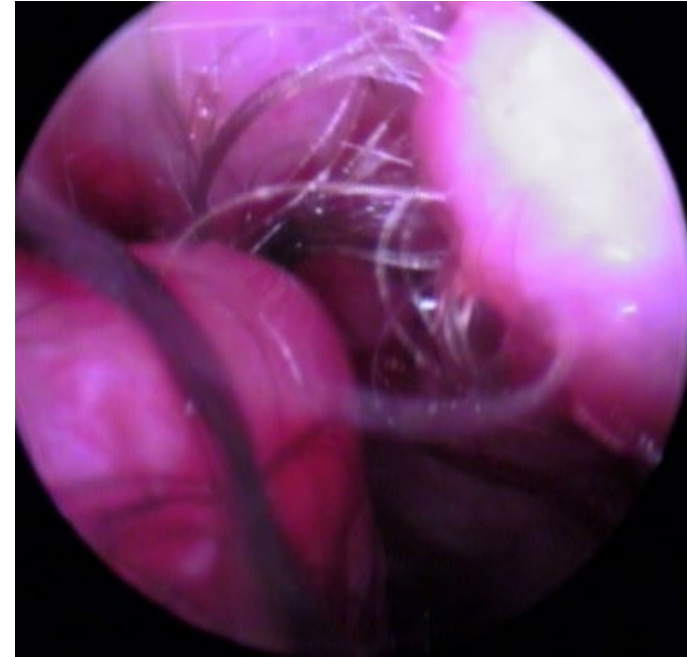
Chronic hyperplastic otitis – cocker spaniel



Slimy, purulent exudate with stenosis and nodular hyperplasia



Mixed rod otitis and nuclear streaming



Nodular hyperplasia and stenosis after treatment of infection

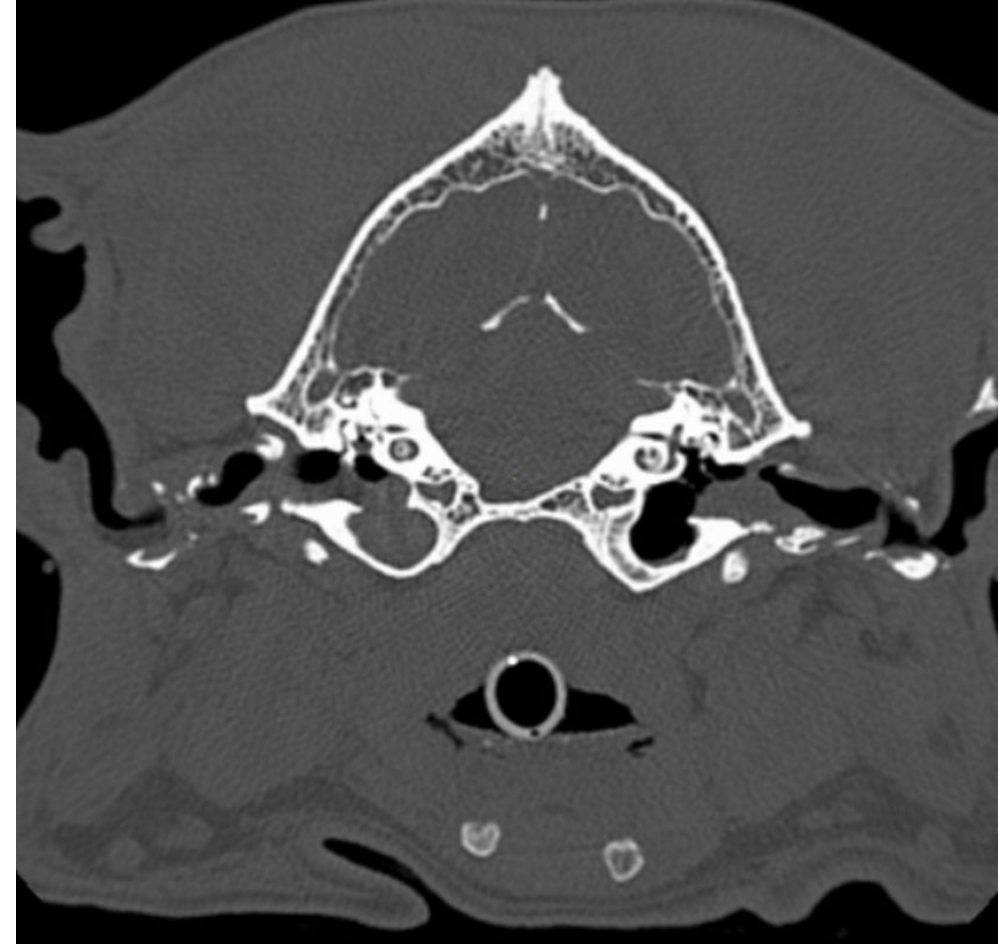Chronic Hyperplastic Otitis- Cocker Spaniel

End Stage Ear Disease

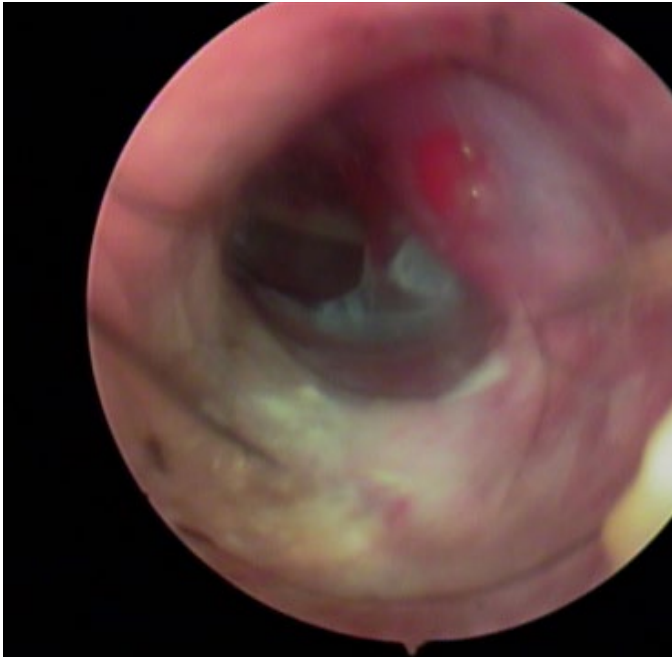
Calcified Ear canals and nodular hyperplasia

Medical management is unlikely to be successful

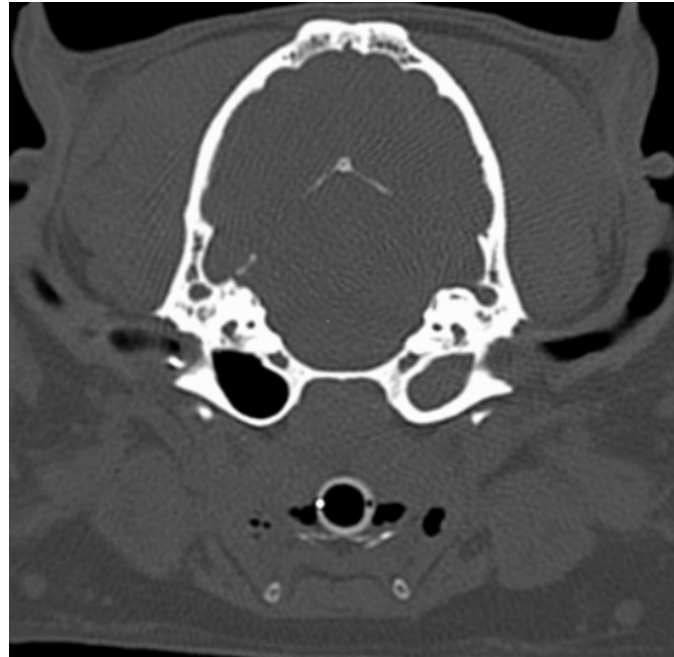
Total ear canal ablation and bulla osteotomy (TECA-BO) is recommended



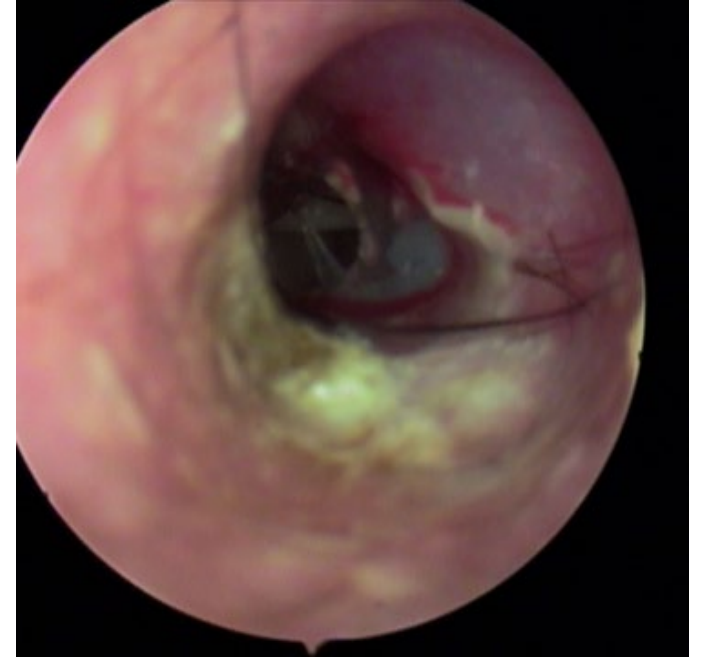
Otitis Media



Large rupture of tympanic membrane, purulent otitis externa



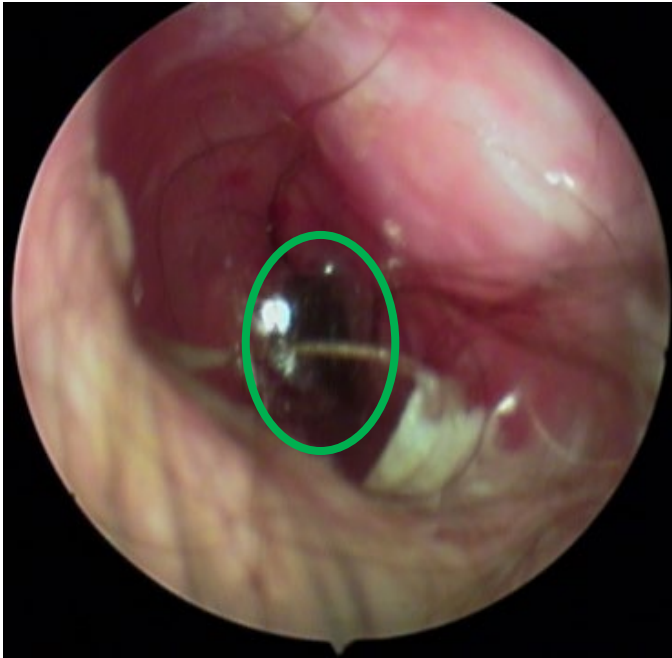
Otitis media, focal calcification of external ear canal



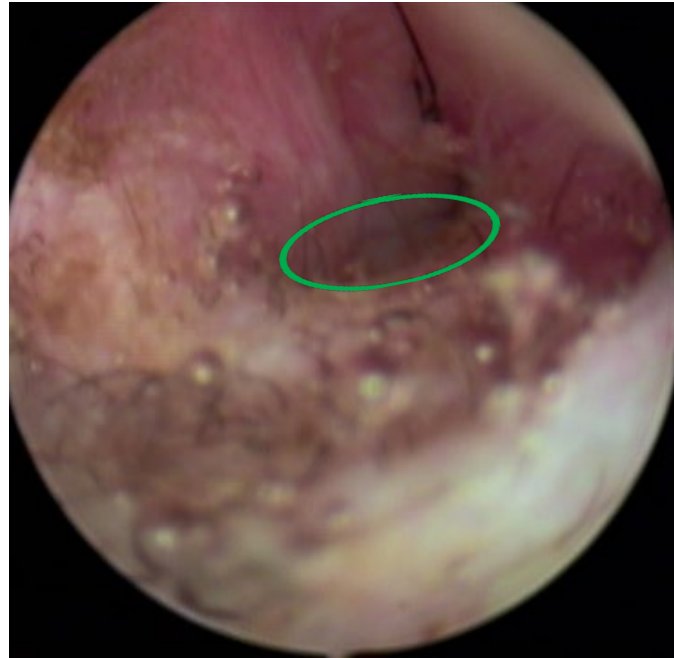Small rupture of tympanic membrane, purulent otitis externa

Otitis media- Brachycephalic dogs

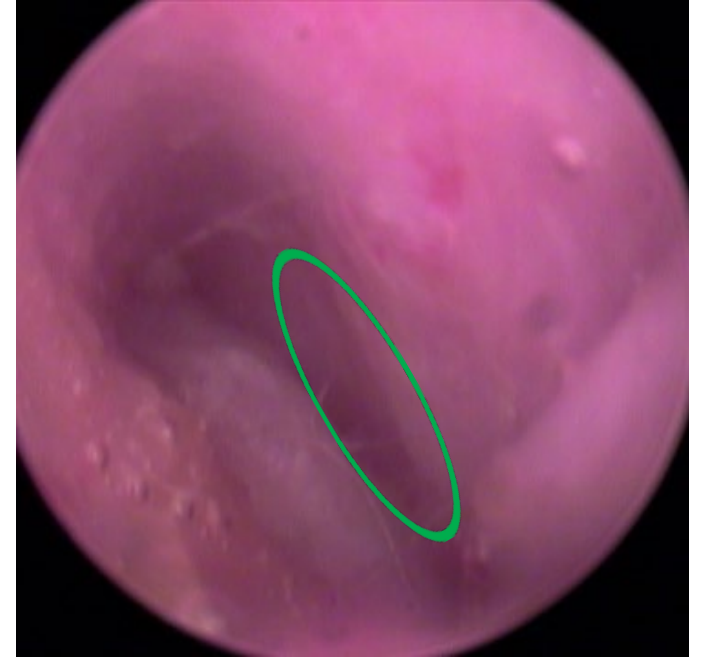French Bulldog



Stenotic horizontal ear canal and purulent otitis externa



Marked stenosis of horizontal canal



Marked stenosis of the horizontal canal

Future Directions

Slide microscopy and IDEXX inVue DX™ require the clinician to correlate the inflammatory cells or infection with the patient's exam findings.

This technology may be especially useful to large mobile units that already have blood analyzers, shelter situations, ER practices, and high-volume private practice



1 Put sample in the reagent.



2 Drop sample into cartridge.



3 Insert and press the Start button


Perform ear cytology on all cases of otitis

Encourage clients to make recheck appointments

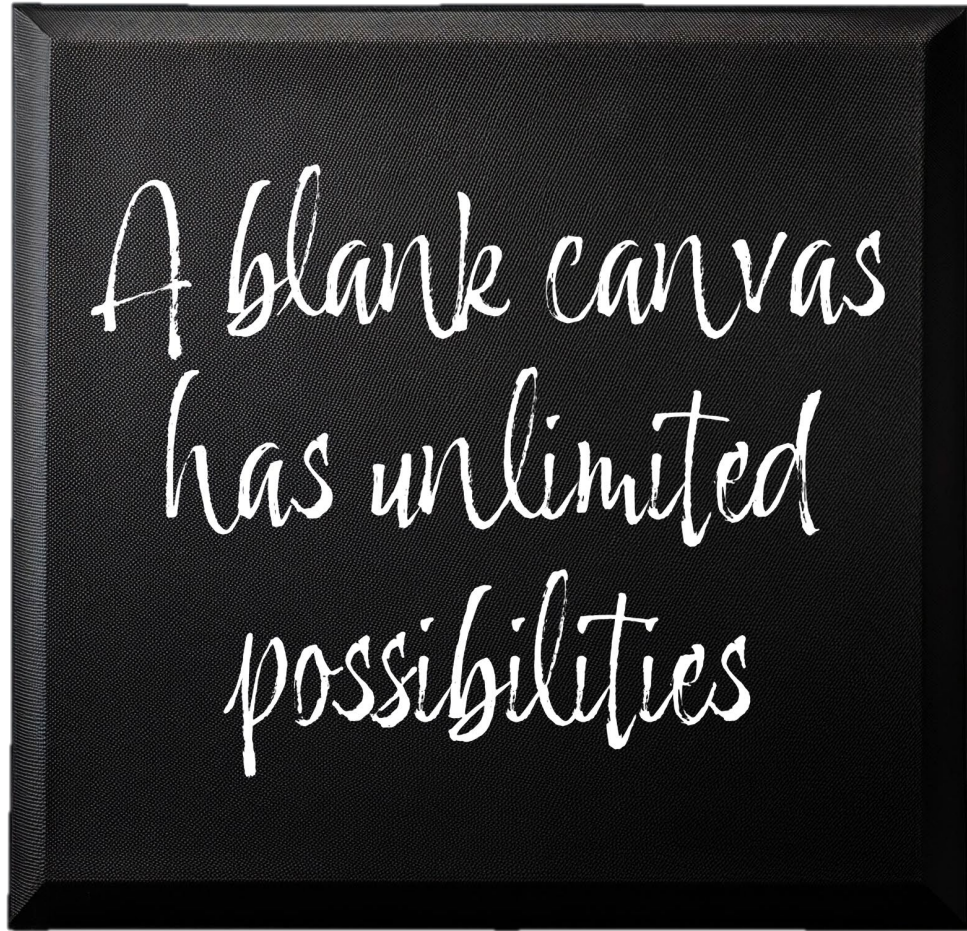
Work through the primary, secondary, and perpetuating factors in repeat offenders

Don't hesitate to refer chronic otitis cases to a Dermatologist

Key Points



Let's paint!



References

- Santoro D. (2023). Comparison of the quantity and antimicrobial activity of host defence peptides in ear canals between healthy and atopic dogs: A preliminary study. *Veterinary dermatology*, 34(5), 452–459. <https://doi.org/10.1111/vde.13164>
- Nuttall T. (2023). Managing recurrent otitis externa in dogs: what have we learned and what can we do better?. *Journal of the American Veterinary Medical Association*, 261(S1), S10–S22. <https://doi.org/10.2460/javma.23.01.0002>
- Rigaut, D., Briantais, P., Jasmin, P., & Bidaud, A. (2024). Efficacy and safety of a hydrocortisone aceponate-containing ear spray solution in dogs with erythemato-ceruminous otitis externa: A randomised, multicentric, single-blinded, controlled trial. *Veterinary dermatology*, 35(2), 197–206. <https://doi.org/10.1111/vde.13224>
- Harvey, R. G., & Patterson, S. (2012). *Otitis Externa, An Essential Guide to Diagnosis and Treatment* (1st ed.). Taylor and Francis Group LLC.
- Miller, WH, Griffin CE, Campbell, KL (2013) Ch19 Diseases of the Eyelids, Claws, Anal Sacs, and Ears in Muller and Kirk's Small Animal Dermatology (7th edition). Saunders
- Patterson, S & Tobias, K. (2013) Atlas of Ear Diseases of the Dog and Cat (1st ed). Wiley-Blackwell